



## Original article

## Comprehensive classification test of scapular dyskinesis: A reliability study

Tsun-Shun Huang<sup>a</sup>, Han-Yi Huang<sup>a</sup>, Tyng-Guey Wang<sup>b</sup>, Yung-Shen Tsai<sup>c</sup>, Jiu-Jenq Lin<sup>a,\*</sup><sup>a</sup> School and Graduate Institute of Physical Therapy, College of Medicine, National Taiwan University, Taiwan, ROC<sup>b</sup> Department of Physical Medicine and Rehabilitation, National Taiwan University Hospital, Taiwan, ROC<sup>c</sup> Graduate Institute of Sports Equipment Technology, University of Taipei, Taiwan, ROC

## ARTICLE INFO

## Article history:

Received 16 June 2014

Received in revised form

17 October 2014

Accepted 28 October 2014

## Keywords:

Scapular dyskinesis

Reliability

Classification

## ABSTRACT

**Background:** Assessment of scapular dyskinesis (SD) is of clinical interest, as SD is believed to be related to shoulder pathology. However, no clinical assessment with sufficient reliability to identify SD and provide treatment strategies is available.

**Objectives:** The purpose of this study was to investigate the reliability of the comprehensive SD classification method.

**Design:** Cross-sectional reliability study.

**Method:** Sixty subjects with unilateral shoulder pain were evaluated by two independent physiotherapists with a visual-based palpation method. SD was classified as single abnormal scapular pattern [inferior angle (pattern I), medial border (pattern II), superior border of scapula prominence or abnormal scapulohumeral rhythm (pattern III)], a mixture of the above abnormal scapular patterns, or normal pattern (pattern IV). The assessment of SD was evaluated as subjects performed bilateral arm raising/lowering movements with a weighted load in the scapular plane. Percentage of agreement and kappa coefficients were calculated to determine reliability.

**Results:** Agreement between the 2 independent physiotherapists was 83% (50/60, 6 subjects as pattern III and 44 subjects as pattern IV) in the raising phase and 68% (41/60, 5 subjects as pattern I, 12 subjects as pattern II, 12 subjects as pattern IV, 12 subjects as mixed patterns I and II) in the lowering phase. The kappa coefficients were 0.49–0.64.

**Conclusions:** We concluded that the visual-based palpation classification method for SD had moderate to substantial inter-rater reliability. The appearance of different types of SD was more pronounced in the lowering phase than in the raising phase of arm movements.

© 2014 Elsevier Ltd. All rights reserved.

The scapula plays several roles in normal shoulder function. First, the scapula functions as a stable part of glenohumeral articulation. Appropriate alignment of the glenoid allows a congruent socket for the moving arm and maximizes concavity compression for shoulder joint stability (Matsen et al., 1991). Second, the scapula provides 3-dimensional movements in order for proper shoulder function to occur. During arm elevation, the scapula synchronously rotates upward, tilts posteriorly, and rotates externally to elevate the acromion to clear the subacromial space and thus avoid impingement (Ludewig and Cook, 2000; Neumann, 2010). Third, it is a link in a proximal-to-distal kinetic chain stretching from the ground, through the trunk and scapula, and to the end of the hand (Kibler, 1998). Appropriate scapular control allows efficient energy

and force transfer to achieve shoulder function. Failure of the scapula to perform these roles results in insufficient physiology and biomechanics. This insufficiency may be related to decreased shoulder performance and shoulder injuries.

Scapular dyskinesis is defined as alteration of scapular position and motion (Kibler et al., 2013). These include an abnormal scapula medial border and inferior angle prominence relative to the thoracic cage in the static position or dynamic motion, early scapula elevation or shrugging on arm elevation, as well as excessive/inadequate/non-smooth upward and downward rotation of the scapula during arm elevation and lowering (McClure et al., 2009). Scapular dyskinesis has been reported in 68%–100% of patients with shoulder injuries, including glenohumeral instability, rotator cuff abnormalities, and labral tears (Warner et al., 1992; Paletta et al., 1997; Burkhart et al., 2000). Thus, scapular dyskinesis is believed to be related to shoulder pathology.

\* Corresponding author. Tel.: +886 2 3366 8126.

E-mail address: [jiujlin@ntu.edu.tw](mailto:jiujlin@ntu.edu.tw) (J.-J. Lin).

Methods to assess scapular dyskinesis include visual observation (Kibler et al., 2002; McClure et al., 2009; Tate et al., 2009), corrective maneuvers (Kibler et al., 2006; Rabin et al., 2006), measurement of scapular displacement (Odom et al., 2001; Hong et al., 2011), and complicated tools such as 3-D motion analysis systems (Ludewig and Cook, 2000; Tate et al., 2009). In general, complicated motion analysis can provide more quantitative data on movements of the scapula, whereas other measurements are practical in the clinical setting. Measurement of scapular displacement from the trunk is a simple and quantitative method. For example, in the lateral scapular slide test, the scapular position is elevated and measurements taken of the scapular distance from the inferior angle of the scapula to the spinous process of the thoracic spine in the same horizontal line at 0°, 40°, and 90° of glenohumeral abduction in the coronal plane. However, this method can only provide static assessment of scapular position. Corrective maneuvers assess scapular dyskinesis with the method of correction, such as the scapular assistance test. In this test, the examiner corrects the abnormal scapular movement during arm elevation for the subject. The subjective feelings of a decrease in or absence of pain during correction indicates scapular dyskinesis (Rabin et al., 2006). Two visual-based assessments for classifying scapular dyskinesis have been reported (Kibler et al., 2002; McClure et al., 2009). Based on observed specific scapula movements, Kibler et al. (2002) classified different patterns of scapular dyskinesis and reported fair reliability (kappa coefficient = 0.31–0.42) of the classification. Instead of using specific scapula movements, McClure et al. (2009) classified scapular dyskinesis with the degree of observed abnormal movements and reported moderate to substantial reliability (kappa coefficient = 0.48–0.61) of the method. In view of these studies, we wanted to use the concepts of several tests to create a comprehensive test with sufficient reliability for identifying appropriate treatment strategies for patients with scapular dyskinesis. Visual observation with palpation based on the degree of a specific pattern of scapular dyskinesis may increase the reliability of the method and help clinicians to identify appropriate treatment strategies corresponding to specific types of scapular dyskinesis.

The purpose of this study was to investigate the reliability of a comprehensive scapular dyskinesis classification test. Different types of scapular dyskinesis were also assessed during raising and lowering phases of arm movements separately.

## 1. Methods

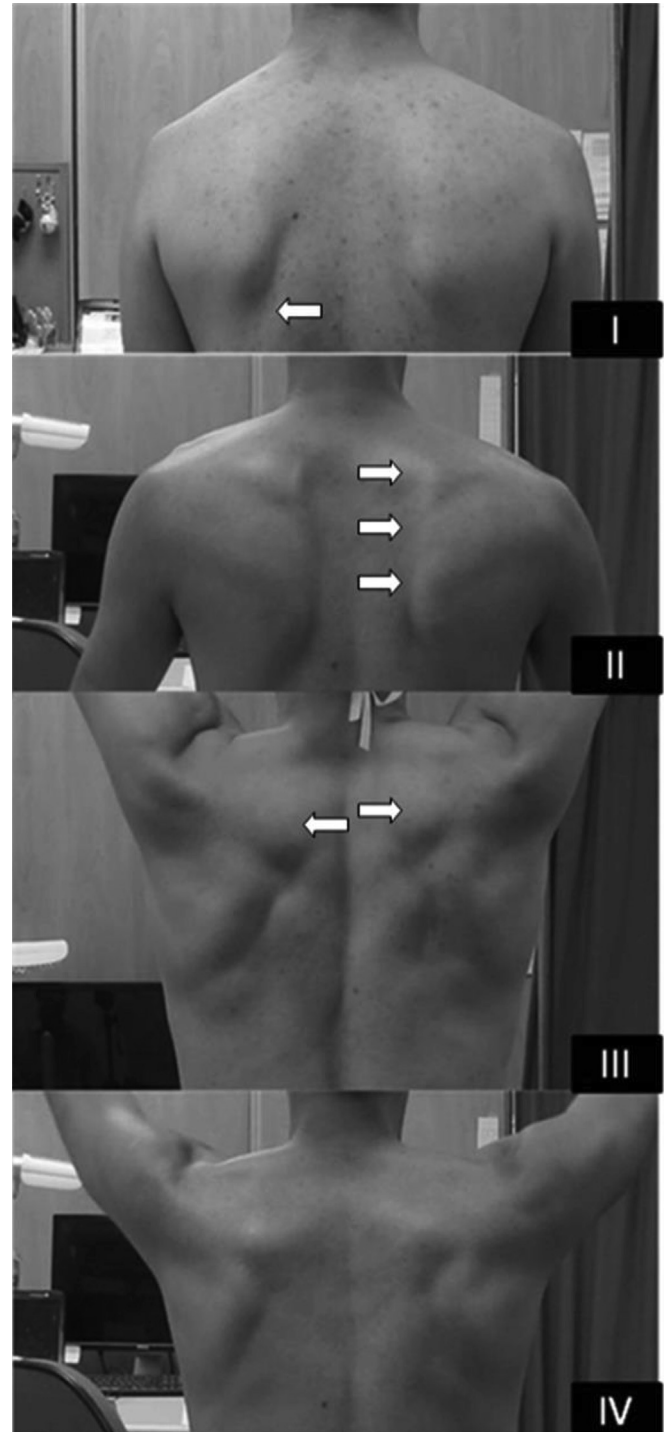
### 1.1. Subjects

Sixty subjects (45 males and 15 females, age:  $22.5 \pm 2.6$ ) were recruited from an outpatient clinic at a university hospital and through local Internet media. For the study, they read and signed the informed consent approved by the hospital institutional review board. Subjects were included if they (1) were from 18 to 50 years old and (2) had unilateral shoulder pain around the shoulder complex while performing functional activities, occupational tasks, or sports-specific movements. Subjects were excluded if they had a history of shoulder dislocation, fracture, or shoulder surgery within the past 1 year, or a history of direct contact injury to the neck or upper extremities within the past 1 month. Subjects who had scoliosis with uneven shoulder level or neurological disorders and those who demonstrated more than mild pain (VAS > 3) during the arm elevation in the scapular plane were also excluded.

### 1.2. Comprehensive scapular dyskinesis classification test

The comprehensive method combined visual observation and palpation of the scapula during arm movements with weighted loads to investigate the scapular patterns in the raising and

lowering phases separately. This method was modified from previous pattern and severity classification methods and added new points (Kibler et al., 2002; McClure et al., 2009). Visual combined palpation ratings were determined at the time of testing based on classification of the scapular position and movement pattern into 4 main patterns (Fig. 1) (Kibler et al., 2002; Lewis et al., 2002; McClure et al., 2009). The inferior angle of the scapula



**Fig. 1.** Rating of scapular dyskinesis classification test. (A) Inferior angle of scapula (pattern I) (B) Medial border of scapula (pattern II) (C) Superior border of scapula (pattern III) (D) Normal movement (pattern IV). The arrow indicates the relevant characteristics specific to the pattern of scapular dyskinesis.

**Table 1**  
Detailed descriptions of scapular dyskinesis patterns.

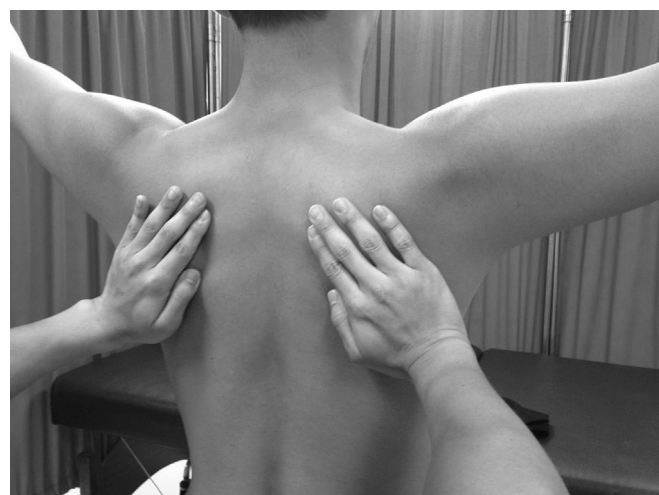| Pattern             | Descriptions   |
|---------------------|--|
| Pattern I           | Inferior medial angle of the scapula is displaced posteriorly from the posterior thorax, prominent during dynamic observation and palpation  |
| Pattern II          | Entire medial border of the scapula is displaced posteriorly from the posterior thorax, prominent during dynamic observation and palpation   |
| Pattern III         | Early scapular elevation or excessive/insufficient scapular upward rotation (dysrhythmia) during dynamic observation and palpation compared to asymptomatic side   |
| Pattern IV (Normal) | 1 No evidence of posterior displacement in medial border/inferior angle of the scapula and excessive/insufficient scapular movement<br>2 Minimal motion during the initial 30–60° of scapulohumeral elevation, then smoothly and continuously rotate upward and downward during humeral elevation and lowering, respectively |
| Mixed patterns      | Mixed condition of above abnormal patterns (1. pattern I + II 2. pattern II + III 3. pattern I + III 4. pattern I + II + III)  |

prominence pattern (pattern I) indicates that the inferior angle of the scapula is displaced posteriorly from the posterior thorax, prominent either at rest or during dynamic movement. The medial border of the scapula prominence pattern (pattern II) represents that the entire medial border of the scapula is displaced posteriorly from the posterior thorax, prominent either at rest or during dynamic movement. The superior border of the scapula prominence or aberrant scapulohumeral rhythm pattern (pattern III) indicates early elevation or excessive/insufficient movements of the scapula during arm movements. The mixed patterns included any combination of at least 2 abnormal patterns in one subject. Pattern IV represents normal scapular movement, defined as no evidence of abnormality in the resting position or dynamic motions. Detailed descriptions are provided in Table 1.

During the assessment, the normal pattern was identified by the rater if the scapula had minimal motion during the initial 60° of arm elevation and then smooth rotation upward during the arm raising phase, after which the scapula smoothly rotated downward during the arm lowering phase (McClure et al., 2009). For the palpation, the radial hand side of the rater firmly contacted the medial border and inferior angle of the scapula bilaterally, and the 2nd to 5th fingers were placed on the spine of the scapula with 3rd fingertip put on root of spine of scapula (Fig. 2). With palpation during arm elevation, the inferior angle and medial border of the scapula were the focus of the method. If the inferior angle displaced posteriorly from the thoracic cage at the resting position or during arm movements, pattern I was designated. Pattern II was designated if the medial border of the scapula displaced posteriorly from the thorax at the resting position or during arm movements. Concurrently, we also observed the angle of scapular upward rotation and distance of scapular elevation relative to the asymptomatic side. If there was early scapular elevation or excessive/insufficient scapular upward rotation between the symptomatic and asymptomatic sides during arm movements, pattern III was identified. If more than two phenomena were observed, mixed patterns were identified.

### 1.3. Procedures

After signing the consent form, male participants were asked to remove their shirts, and females were asked to wear halter tops. Subjects were instructed to practice arm elevations in the scapular



**Fig. 2.** Palpation method of scapular dyskinesis classification test. For the palpation, the radial hand side of the rater firmly contacted the medial border and inferior angle of the scapula bilaterally, and the 2nd to 5th fingers were placed on the spine of the scapula with the 3rd fingertip on the root of the spine of the scapula.

plane following a target line and to become familiar with the tempo of a metronome to precisely perform movements at the same pace. Beginning in a standing position, subjects let both arms hang at the sides of the body with the elbows straight and shoulders in neutral position. Then subjects were asked to elevate their arms with dumbbells in their hands with their thumbs up to the end position over a 3-s count, and then to lower the arms to the initial position over a 3-s count. The weight of the dumbbell in each hand was 2.3 kg (5 lb) or 1.4 kg (3 lb), depending on the subjects' ability to elevate the arm without discomfort (VAS less than 3/10) during movements. For the assessment, subjects elevated and lowered both arms 12 times. Because palpation could not be performed by the two raters simultaneously, we used cross-rating based on visual observation and palpation over 12 trials to reduce the influence of fatigue or other confounding factors during assessments. For the cross-rating, the first rater evaluated the 1st, 3rd, 5th, 7th, 9th, and 11th trials of arm elevation, and the second rater evaluated the 2nd, 4th, 6th, 8th, 10th, and 12th trials. The subject completed one trial at a time, and the raters would alternate for evaluation. Each rater independently rated the testing movements without discussion. An abnormal scapula pattern was rated if it was identified in at least 3 of 6 trials for each rater during the movements. Both raters were physical therapists holding a Master's Degree and licensed in Taiwan, and both had specific clinical/research experience related to glenohumeral and/or scapulothoracic joints. In order to classify the scapular patterns appropriately, they received 2 months of training on identifying the scapular patterns. The training consisted of studying instructional slides and photographs with specific patterns of scapular dyskinesis and evaluating several pilot subjects.

### 1.4. Statistical analysis

The inter-rater reliability for the comprehensive scapular dyskinesis classification test was determined using percentage of agreement and  $\kappa$  coefficient. The  $\kappa$  coefficient was defined as 0.8 excellent, 0.61–0.8 substantial, 0.41–0.6 moderate, 0.21–0.4 fair, and 0–0.2 slight/poor (Landis and Koch, 1977). For Cohen's kappa, we analyzed the reliability with categorical data and applied this method with two raters and multiple patients in this study.

**Table 2**  
Participant demographic data.

| Total                              | Male  |      | Female |      |
|------------------------------------|-------|------|--------|------|
|                                    | Mean  | SD   | Mean   | SD   |
| Number                             | 45    |      | 15     |      |
| Age (yrs)                          | 22.8  | 2.8  | 21.8   | 1.7  |
| Height (cm)                        | 175.1 | 6.5  | 162.2  | 6.6  |
| Weight (kg)                        | 66.1  | 7.4  | 55.3   | 6.2  |
| Duration of symptoms (months)      | 20.3  | 24.8 | 29.7   | 49.8 |
| Dominant side                      | R:41  |      | R:15   |      |
| Involved side                      | R:37  |      | R:13   |      |
| Pain (activity) (VAS) <sup>a</sup> | 3.5   | 1.4  | 4.3    | 1.5  |

Abbreviations: M, Male; VAS, visual analog scale; R, right side.

<sup>a</sup> Pain level while performing functional activities, occupational tasks, or sports-specific movements (not during arm elevation).

## 2. Results

The demographic data of subjects are shown in Table 2. For the raising phase, classifications from 2 raters were in agreement on 50/60 subjects (83%). For the agreement classifications, 6 subjects were classified as superior border of scapula (pattern III), and the other 44 subjects were classified as normal movement (pattern IV). For the lowering phase, classifications from 2 raters were in agreement on 41/60 subjects (68%). For the agreement classifications, 5 subjects were classified as inferior angle of scapula (pattern I), 12 subjects were classified as medial border of scapula (pattern II), 12 subjects were classified as normal movement (pattern IV), and the other 12 subjects were classified as mixed pattern of I and II. Detailed values of agreement and disagreement on different patterns in the raising and lowering phases are presented in Table 3. The  $\kappa$  coefficients were 0.49–0.64. The  $\kappa$  coefficients of the raising phase reached the moderate level ( $\kappa = 0.49$ ), and those in the lowering phase reached the moderate to substantial level ( $\kappa = 0.57$ –0.64).

## 3. Discussion

Using our comprehensive scapular dyskinesis classification test, we found that the method had moderate to substantial inter-rater reliability. This comprehensive test consisted of several important characteristic. First, combined palpation can reduce the difficulty of determining the scapular patterns because of the surrounding soft tissues. Second, compared to previous classification methods using a single pattern (Kibler et al., 2002; McClure et al., 2009; Tate et al., 2009; Wright et al., 2013), our classification methods evaluate scapular dyskinesis based on both single and mixed patterns. This is important when considering the common occurrence of mixed

**Table 3**  
Case classification of agreement and disagreement on different patterns of scapular dyskinesis in raising and lowering phases.

| Rater 2      | rater 1 | I               | II                             | III                             | I + II          | I + III | II + III       | I + II + III   | IV                              | Total                           |
|--------------|---------|-----------------|--------------------------------|---------------------------------|-----------------|---------|----------------|----------------|---------------------------------|---------------------------------|
| I            |         | 5 <sup>L</sup>  | 1 <sup>L</sup>                 |                                 | 2 <sup>L</sup>  |         |                |                |                                 | 8 <sup>L</sup>                  |
| II           |         | 1 <sup>L</sup>  | 12 <sup>L</sup>                |                                 |                 |         |                |                | 1 <sup>R</sup>                  | 1 <sup>R</sup> 13 <sup>L</sup>  |
| III          |         |                 | 1 <sup>R</sup>                 | 6 <sup>R</sup>                  |                 |         |                | 1 <sup>R</sup> |                                 | 8 <sup>R</sup>                  |
| I + II       |         | 4 <sup>L</sup>  | 4 <sup>L</sup>                 |                                 | 12 <sup>L</sup> |         |                |                |                                 | 20 <sup>L</sup>                 |
| I + III      |         |                 |                                |                                 |                 |         |                |                |                                 |                                 |
| II + III     |         |                 | 1 <sup>L</sup>                 |                                 |                 |         |                |                |                                 | 1 <sup>L</sup>                  |
| I + II + III |         |                 |                                |                                 |                 |         |                |                |                                 |                                 |
| IV           |         | 1 <sup>L</sup>  | 1 <sup>R</sup> 2 <sup>L</sup>  | 6 <sup>R</sup> 3 <sup>L</sup>   |                 |         |                |                | 44 <sup>R</sup> 12 <sup>L</sup> | 51 <sup>R</sup> 18 <sup>L</sup> |
| Total        |         | 12 <sup>L</sup> | 2 <sup>R</sup> 19 <sup>L</sup> | 12 <sup>R</sup> 17 <sup>L</sup> |                 |         | 1 <sup>R</sup> |                | 45 <sup>R</sup> 12 <sup>L</sup> | 60 <sup>R</sup> 60 <sup>L</sup> |

<sup>R</sup>: raising phase; <sup>L</sup>: lowering phase; agreement in grey highlight. There was 83% agreement (50/60, 6 subjects as pattern III and 44 subjects as pattern IV) with kappa = 0.49 in the raising phase and 68% agreement (41/60, 5 subjects as pattern I, 12 subjects as pattern II, 12 subjects as pattern IV, 12 subjects as mixed patterns I and II) with kappa = 0.57–0.64 in the lowering phase between 2 physiotherapists.

patterns in scapular dyskinesis. In our study, 27 subjects presented mixed patterns, which showed the importance of classifying mixed patterns. We believe the characteristics of different patterns of scapular dyskinesis could be related to different treatment strategies. Third, we found that the patterns were different in the raising and lowering phases: Patterns III and IV were dominant in the raising phase, but patterns I, II, mixed I and II, and IV were dominant in the lowering phase. Thus, using a single pattern of classification for analyzing both the raising and the lowering phases was not appropriate. Finally, we also believe that weighted tasks, which are commonly seen in functional or sports-specific tasks, are more challenging and appropriate for validation of scapular dyskinesis. In our data, scapular dyskinesis occurred more in weighted tasks than in non-weighted tasks. These may explain why the reliability found in our study reached moderate to substantial level which was higher than the original Kibler's 4 type method (fair to moderate) and similar to the severity method (Kibler et al., 2002; McClure et al., 2009; Tate et al., 2009). Table 4 summarizes the scapular dyskinesis visual classification of our comprehensive classification method and previous methods. Reviewing scapular physical tests from the literature, Wright et al. (2013) indicated a need for an appropriate method of diagnosis and treatment of scapular dyskinesis. Our comprehensive method may provide a clinical classification for scapular dyskinesis.

In the analysis of the distribution of the ratings by the two raters, we found that more patterns were observed in the lowering phases. In agreement with previous findings (Kibler et al., 2002), both raters found that the appearance of posterior displacement of the medial border and the inferior angle of the scapula were more pronounced in the lowering phase than in the raising phase. An explanation for the greater pronounced classification in the arm-lowering phase could be that the lowering phase represents eccentric loading of less muscle activity during movements, which makes bony landmarks prominent for visualization/palpation. Additionally, our method assessed scapular dyskinesis based on both unilateral characteristics and side-to-side comparison. Based on unilateral assessment, the detection of abnormal scapulohumeral rhythm was difficult because normal scapulohumeral rhythm does not entirely conform to the generally accepted 2:1 ratio throughout the full range of arm elevation (Inman et al., 1996; Ebaugh and Spinelli, 2010; Scibek and Carcia, 2012). Thus, side-to-side comparison allows the rater to assess patterns of dyskinesis precisely and reliably (Oyama et al., 2008; McClure et al., 2009).

Unlike the single predominant rating method, our method adds the mixed patterns for evaluation. Although the mixed patterns are common and necessary for evaluation, selection among the mixed patterns may present another dilemma. Due to continuity from the scapular inferior angle to the medial border, it may be difficult to determine a rating of pattern I, pattern II, or mixed patterns. In our study, the rating disagreement between the 2 raters occurred mostly in the classification of these patterns (12/19 in the lowering phase). Definitions of these patterns need to be clarified. We suggest that the inferior third of the medial border can be used to distinguish between the inferior angle pattern and the medial border pattern. Pattern II can be identified if winging occurs above the inferior third of the medial border. Otherwise, if only the inferior angle of scapula is displaced from thorax, pattern I can be identified. When both the medial border of the scapula and the lateral border of the inferior angle are obviously displaced posteriorly from the thorax, the mixed pattern can be determined. One noteworthy finding is that there was no agreement of ratings between the 2 raters on pattern III in the lowering phase. Investigating shoulder kinematics in healthy subjects, several studies have suggested that pattern of scapular upward/downward rotation is similar between two phases (Yoshizaki et al., 2009; Ebaugh and

**Table 4**

Visual classification of scapular dyskinesis: comparison between comprehensive method of the present study and methods from previous studies.

| Studies characteristics        | Kibler et al., 2002                      | McClure et al., 2009 Tate et al., 2009                          | Uhl et al., 2009                         | Present study   |
|--------------------------------|--|---|--|---|
| Rating criteria                | Dynamic pattern: side-to-side comparison | Dynamic severity: absolute definition                           | Dynamic pattern: side-to-side comparison | Dynamic pattern: absolute definition plus side-to-side comparison |
| Arm raising or lowering phases | Total                                    | Total   | Total                                    | Separated raising and lowering phases                             |
| Live or video                  | Video                                    | Live and video  | Live                                     | Live  |
| Additional load                | No                                       | Yes   | No                                       | Yes   |
| Pattern evaluation             | 4 single patterns                        | NA (3 severity level)   | 2 patterns (yes/no)                      | 4 single patterns and mixed patterns                              |
| Reliability                    | Fair to moderate (kappa = 0.31–0.42)     | Moderate to substantial (kappa = 0.48–0.61; agreement = 75–82%) | Moderate (kappa = 0.41; agreement = 79%) | Moderate to substantial (kappa = 0.49–0.64; agreement = 68–83%)   |

Spinelli, 2010; Matsuki et al., 2011; Warner et al., 2012). However, in our sample with shoulder disorders, we observed that scapulothoracic movements are not only different between raising and lowering phases but also difficult to determine in the lowering phase. Further studies to validate the findings are needed.

Despite the departure from all previous methods, our separation of the raising and lowering phases during evaluation was necessary because of the findings of the more obvious inferior angle and medial border of scapular prominence in the arm-lowering phase. Investigating muscular activation during movement, previous studies found significant decreases in muscular activation during eccentric contraction (Ebaugh and Spinelli, 2010; Fang et al., 2001, 2004). Since a certain level of scapulothoracic muscle activity (activation threshold) is necessary to produce normal scapulothoracic motion, decreased muscular activation during arm lowering, such that the activation threshold is not reached, may result in scapular dyskinesis due to compromised control of scapulothoracic motion. Consequently, this method of separation of the raising and lowering phases may be used to evaluate scapular motion in different conditions and represent different scapular dyskinesis patterns in each phase.

The limitations of our investigation should be noted. First, the 2 raters were in the same room and saw what the other rater was doing, so disagreement may have been reduced during evaluation. In our design, the 2 raters evaluated every other repetition of the arm elevation continuously in the same room and were able to watch what each other was doing. Although each rater could observe what the other rater was doing, it was not possible to distinguish what the other rater was focusing on. Since the evaluation procedure was similar and the raters did not know each other's assessment results, we believe that the effect of blinding was adequate. Second, intra-rater reliability was not tested in this study. Since we did not assess the subjects by video, blinding the subjects to the raters was not possible, as memory washout was not possible for the rater. Thus, we reported inter-rater reliability only. Third, the participating population was aged between 18 and 33, 85% of whom participated in overhead sports and 15% of whom participated in non-overhead sports. Patterns of scapular dyskinesis may be affected by participation in sports activities. The generalization of the findings of the study to other age groups or people with sedentary lifestyles is uncertain. The operational definition of the scapular dyskinesis classification test in the arm-raising and -lowering phases may need to be made more detailed in order to resolve the vague boundaries of each pattern.

#### 4. Conclusion

A comprehensive scapular dyskinesis classification test combining both visual and palpation methods has satisfactory

inter-rater reliability. For the classification test, both raising and lowering phases should be evaluated, with a focus especially on prominent landmarks for visualization/palpation during the lowering phase. Future studies can investigate the validity of this test to determine whether specific scapular kinematics and muscular activation correspond to each pattern of scapular dyskinesis. If there are specific findings in different patterns of scapular dyskinesis, we can identify appropriate treatment strategies for patients with different patterns of scapular dyskinesis.

#### References

- Burkhart SS, Morgan CD, Kibler WB. Shoulder injuries in overhead athletes. The "dead arm" revisited. *Clin Sports Med* 2000;19:125–58.
- Ebaugh DD, Spinelli BA. Scapulothoracic motion and muscle activity during the raising and lowering phases of an overhead reaching task. *J Electromyogr Kinesiol* 2010;20:199–205.
- Fang Y, Siemionow V, Sahgal V, Xiong F, Yue GH. Greater movement-related cortical potential during human eccentric versus concentric muscle contractions. *J Neurophysiol* 2001;86:1764–72.
- Fang Y, Siemionow V, Sahgal V, Xiong F, Yue GH. Distinct brain activation patterns for human maximal voluntary eccentric and concentric muscle actions. *Brain Res* 2004;1023:200–12.
- Hong J, Barnes MJ, Leddon CE, Van Rysseghem G, Alamar B. Reliability of the sitting hand press-up test for identifying and quantifying the level of scapular medial border posterior displacement in overhead athletes. *Int J Sports Phys Ther* 2011;6:306–11.
- Inman VT, Saunders JB, Abbott LC. Observations of the function of the shoulder joint. 1944. *Clin Orthop Relat Res* 1996;3–12.
- Kibler WB. The role of the scapula in athletic shoulder function. *Am J Sports Med* 1998;26:325–37.
- Kibler WB, Ludewig PM, McClure PW, Michener LA, Bak K, Sciascia AD. Clinical implications of scapular dyskinesis in shoulder injury: the 2013 consensus statement from the "Scapular Summit". *Br J Sports Med* 2013;47:877–85.
- Kibler WB, Sciascia A, Dome D. Evaluation of apparent and absolute supraspinatus strength in patients with shoulder injury using the scapular retraction test. *Am J Sports Med* 2006;34:1643–7.
- Kibler WB, Uhl TL, Maddux JW, Brooks PV, Zeller B, McMullen J. Qualitative clinical evaluation of scapular dysfunction: a reliability study. *J Shoulder Elbow Surg* 2002;11:550–6.
- Landis JR, Koch GG. The measurement of observer agreement for categorical data. *Biometrics* 1977;33:159–74.
- Lewis J, Green A, Reichard Z, Wright C. Scapular position: the validity of skin surface palpation. *Man Ther* 2002;7:26–30.
- Ludewig PM, Cook TM. Alterations in shoulder kinematics and associated muscle activity in people with symptoms of shoulder impingement. *Phys Ther* 2000;80:276–91.
- Matsen 3rd FA, Harryman 2nd DT, Sidles JA. Mechanics of glenohumeral instability. *Clin Sports Med* 1991;10:783–8.
- Matsuki K, Matsuki KO, Mu S, Yamaguchi S, Ochiai N, Sasho T, et al. In vivo 3-dimensional analysis of scapular kinematics: comparison of dominant and nondominant shoulders. *J Shoulder Elbow Surg* 2011;20:659–65.
- McClure P, Tate AR, Kareha S, Irwin D, Zlupko E. A clinical method for identifying scapular dyskinesis, part 1: reliability. *J Athl Train* 2009;44:160–4.
- Neumann DA. Kinesiology of the musculoskeletal system: foundations for physical rehabilitation. 2nd ed. Philadelphia: Mosby; 2010.
- Odom CJ, Taylor AB, Hurd CE, Denegar CR. Measurement of scapular asymmetry and assessment of shoulder dysfunction using the lateral scapular slide test: a reliability and validity study. *Phys Ther* 2001;81:799–809.

- Oyama S, Myers JB, Wassinger CA, Daniel Ricci R, Lephart SM. Asymmetric resting scapular posture in healthy overhead athletes. *J Athl Train* 2008;43:565–70.
- Paletta Jr GA, Warner JJ, Warren RF, Deutsch A, Altchek DW. Shoulder kinematics with two-plane x-ray evaluation in patients with anterior instability or rotator cuff tearing. *J Shoulder Elbow Surg* 1997;6:516–27.
- Rabin A, Irrgang JJ, Fitzgerald GK, Eubanks A. The intertester reliability of the scapular assistance test. *J Orthop Sports Phys Ther* 2006;36:653–60.
- Scibek JS, Carcia CR. Assessment of scapulohumeral rhythm for scapular plane shoulder elevation using a modified digital inclinometer. *World J Orthop* 2012;3:87–94.
- Tate AR, McClure P, Kareha S, Irwin D, Barbe MF. A clinical method for identifying scapular dyskinesis, part 2: validity. *J Athl Train* 2009;44:165–73.
- Uhl TL, Kibler WB, Gecewich B, Tripp BL. Evaluation of clinical assessment methods for scapular dyskinesis. *Arthroscopy* 2009;25:1240–8.
- Warner JJ, Micheli LJ, Arslanian LE, Kennedy J, Kennedy R. Scapulothoracic motion in normal shoulders and shoulders with glenohumeral instability and impingement syndrome. A study using Moire topographic analysis. *Clin Orthop Relat Res* 1992:191–9.
- Warner MB, Chappell PH, Stokes MJ. Measuring scapular kinematics during arm lowering using the acromion marker cluster. *Hum Mov Sci* 2012;31:386–96.
- Wright AA, Wassinger CA, Frank M, Michener LA, Hegedus EJ. Diagnostic accuracy of scapular physical examination tests for shoulder disorders: a systematic review. *Br J Sports Med* 2013;47:886–92.
- Yoshizaki K, Hamada J, Tamai K, Sahara R, Fujiwara T, Fujimoto T. Analysis of the scapulohumeral rhythm and electromyography of the shoulder muscles during elevation and lowering: comparison of dominant and nondominant shoulders. *J Shoulder Elbow Surg* 2009;18:756–63.