

MICHAEL M. REINOLD, PT, DPT, ATC, CSCS¹ • RAFAEL ESCAMILLA, PT, PhD, CSCS, FACSM² • KEVIN E. WILK, PT, DPT³

Current Concepts in the Scientific and Clinical Rationale Behind Exercises for Glenohumeral and Scapulothoracic Musculature

The biomechanical analysis of rehabilitation exercises has gained recent attention. As our knowledge of specific muscle biomechanics and function has increased, we have seen a gradual progression towards more scientifically based rehabilitation exercises. Several investigators have sought to describe common rehabilitation exercises using kinematics, kinetics, and electromyographic (EMG) data in an attempt to better understand the implications of each exercise on the soft tissues of the glenohumeral and scapulothoracic joints. Advances in the understanding of the biomechanical factors of rehabilitation have led to the enhancement of rehabilitation programs that seek to facilitate recovery, while placing minimal strain on specific healing structures.

Though the fields of orthopedics and sports medicine have evolved



to emphasize the necessity of evidence-based practice, few studies have been conducted to determine the efficacy of specific shoulder rehabilitation exercises. Thus, knowledge of anatomy, biomechanics, and function of specific musculature is critical in an attempt to develop the most

advantageous rehabilitation programs.

The purpose of this paper is to provide an overview of the biomechanical and clinical implications associated with the rehabilitation of the glenohumeral and scapulothoracic joints. We will review the function and biomechanics of each muscle, with specific emphasis on many commonly performed rehabilitation exercises. The goal of this is to provide the clinician with a thorough overview of the available information to develop safe, potentially effective, and appropriate exercise programs for injury rehabilitation and prevention.

ROTATOR CUFF MUSCLES

THE ROTATOR CUFF HAS BEEN SHOWN to be a substantial dynamic stabilizer of the glenohumeral joint in multiple shoulder positions.^{49,88} Appropriate rehabilitation progression and strengthening of the rotator cuff muscles are important to provide appropriate force to help elevate and move the arm, compress and center the humeral head within the glenoid fossa during shoulder movements (providing dynamic stability), and provide a counterforce to humeral head superior translation resulting from del-

• **SYNOPSIS:** The biomechanical analysis of rehabilitation exercises has led to more scientifically based rehabilitation programs. Several investigators have sought to quantify the biomechanics and electromyographic data of common rehabilitation exercises in an attempt to fully understand their clinical indications and usefulness. Furthermore, the effect of pathology on normal shoulder biomechanics has been documented. It is important to consider the anatomical, biomechanical, and clinical implications when designing exercise

programs. The purpose of this paper is to provide the clinician with a thorough overview of the available literature relevant to develop safe, effective, and appropriate exercise programs for injury rehabilitation and prevention of the glenohumeral and scapulothoracic joints.

• **LEVEL OF EVIDENCE:** Level 5. *J Orthop Sports Phys Ther* 2009; 39(2):105-117. doi:10.2519/jospt.2009.2835

• **KEY WORDS:** electromyography, infraspinatus, serratus anterior, supraspinatus, trapezius

¹Coordinator of Rehabilitation Research and Education, Department of Orthopedic Surgery, Division of Sports Medicine, Massachusetts General Hospital, Boston, MA; Rehabilitation Coordinator/Assistant Athletic Trainer, Boston Red Sox Baseball Club, Boston, MA. ²Professor, Department of Physical Therapy, California State University, Sacramento, Sacramento, CA. ³Clinical Director, Champion Sports Medicine, Director of Rehabilitative Research, American Sports Medicine Institute, Birmingham, AL. Address correspondence to Dr Michael M. Reinold, Rehabilitation Coordinator/Assistant Athletic Trainer, Boston Red Sox Baseball Club, Fenway Park, 4 Yawkey Way, Boston, MA 02215. Email: mreinold@redsox.com

toid activity (minimizing subacromial impingement).^{6,8,9,21,34,50,60,65,74} In addition, rotator cuff muscles are frequently treated either conservatively or surgically secondary to injuries.

Exercise designed to strengthen the muscles of the rotator cuff are often prescribed to patients with pathologies such as subacromial impingement. During scapular plane abduction in healthy subjects, the humeral head translates 1 to 3 mm in the superior direction from 0° to 30° of abduction, slightly inferiorly from 30° to 60° of abduction, and in the superior or inferior direction during 60° to 90° of abduction.^{26,50,67} Other data demonstrate that, during passive scapular plane abduction, the humeral head translates superiorly 0.6 to 1.8 mm between 0° to 150°.^{25,26} But during active scapular plane abduction the humeral head remains nearly centered in the glenoid fossa throughout the range of movement.²⁶ These data illustrate the importance of rotator cuff strength and muscle balance to resist humeral head superior translation and help center the humeral head within the glenoid fossa during shoulder elevation.⁷⁴ With rotator cuff pathology, altered kinematics and muscle activity are present,³¹ and superior humeral head translation increases and subacromial space decreases.²⁴ Moreover, during scapular plane shoulder abduction from 30° to 90°, infraspinatus and subscapularis activity was found to be significantly less in individuals with subacromial impingement compared to those without impingement.⁶⁸

Subjects with shoulder laxity and instability have also been shown to have altered kinematics and firing patterns of the rotator cuff.^{7,35,45,46,55,64,72} Compared to healthy subjects, patients with generalized joint laxity demonstrated increased subscapularis activity during internal rotation (IR) exercise and decreased supraspinatus and subscapularis activity during external rotation (ER) exercise.^{7,43} Compared to healthy subjects, those with anterior instability exhibited less supraspinatus activity between 30° to 60°

of shoulder elevation during abduction and scaption exercises.⁵⁹

These EMG data clearly illustrate aberrant muscle-firing patterns in individuals with shoulder pathology. It is often the goal of rehabilitation specialists to prescribe exercises to normalize or prevent these abnormal firing patterns. Proper selection of exercises to activate muscle function for each muscle of the rotator cuff should be considered during rehabilitation.

Supraspinatus

The supraspinatus compresses, abducts, and generates a small ER torque to the glenohumeral joint. Supraspinatus activity increases as resistance increases during abduction/scaption movements, peaking at 30° to 60° of elevation for any given resistance. At lower elevation angles, supraspinatus activity increases, providing additional humeral head compression within the glenoid fossa to counter the humeral head superior translation occurring with contraction of the deltoid.¹ Due to a decreasing moment arm with abduction, the supraspinatus is a more effective abductor in the scapular plane at smaller abduction angles.^{34,50,65}

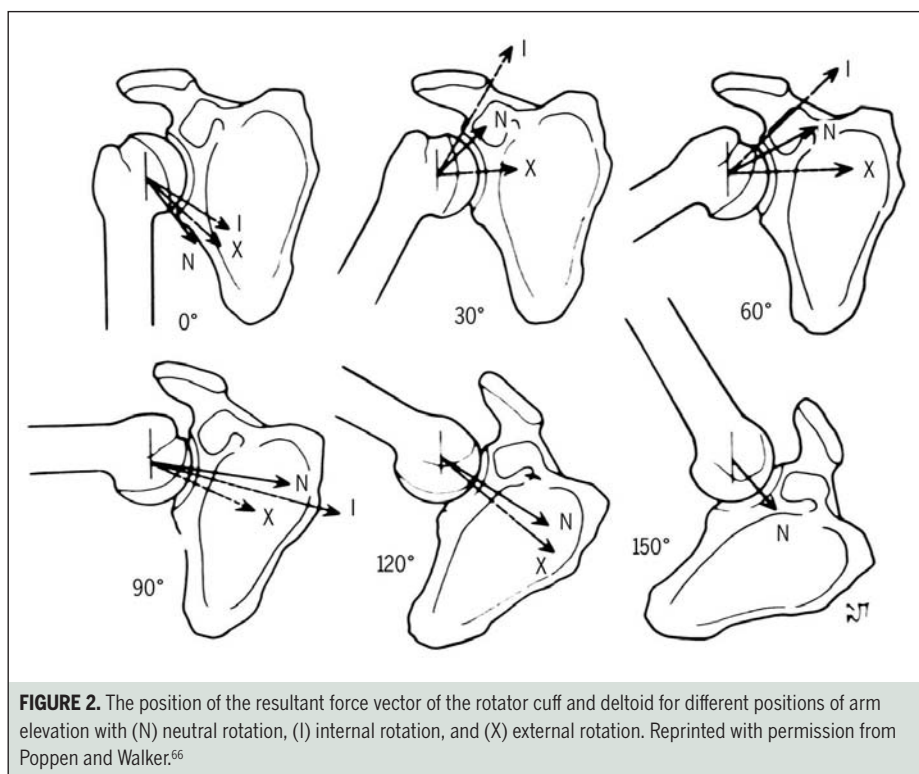
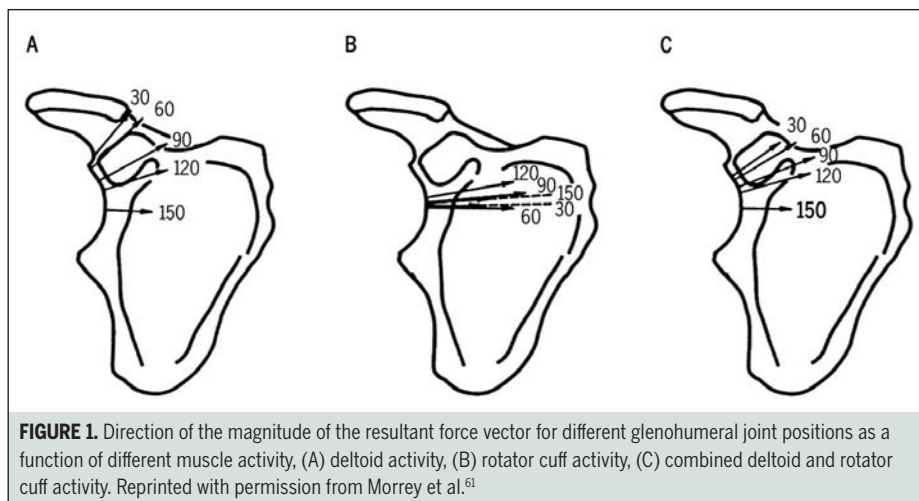
Relatively high supraspinatus activity has been measured in several common rotator cuff exercises^{3,5,17,33,54,63,70,75,79,87} and in several exercises that are not commonly thought of as rotator cuff exercises, such as standing forward scapular punch, rowing exercises, push-up exercises, and 2-hand overhead medicine ball throws.^{13,17,32,81} These results suggest the importance of the rotator cuff in providing dynamic glenohumeral stability by centering the humeral head within the glenoid fossa during all upper extremity functional movements. This is an important concept for the clinician to understand. The muscle's ability to generate abduction torque in the scapular plane appears to be greatest with the shoulder in neutral rotation or in slight IR or ER.^{50,65} This biomechanical advantage has led to the development of exercises in the plane of the

scapula to specifically strengthen the supraspinatus.³⁸

Jobe³⁸ was the first to recommend elevation in the scapular plane (30° anterior to the frontal plane) with glenohumeral IR, or the “empty can” exercise, to strengthen the supraspinatus muscle. Other authors^{37,40,66,69,70,77} have suggested the “full can” position, or elevation in the scapular plane with glenohumeral ER, to best strengthen and test the supraspinatus muscle. Furthermore, compared to the empty can exercise, Blackburn⁵ reported significantly greater supraspinatus activity during prone horizontal abduction at 100° with full ER, or prone full can, position. The results of studies comparing these exercises provide inconsistent results due to methodological limitations, including lack of statistical analysis,^{38,79} lack of data for all 3 exercises,^{40,54,79,87} and absence of data on deltoid muscle activity.⁸⁷

Recently, Reinold et al⁶⁹ comprehensively evaluated the EMG signal of the supraspinatus and deltoid musculature during the full can, empty can, and prone full can exercises in an attempt to clarify the muscular activation during these exercises. The results showed that all 3 exercises provide a similar amount of supraspinatus activity ranging from 62% to 67% of maximal voluntary isometric contraction (MVIC). However, the full can exercise demonstrated a significantly lower amount of middle and posterior deltoid activity compared to the 2 other exercises. This is clinically significant when trying to strengthen the supraspinatus while simultaneously minimizing potentially disadvantageous superior shear force due to deltoid activity.

In patients with shoulder pain, weakness of the rotator cuff, or inefficient dynamic stabilization, it is the authors' opinion that activities that produce higher levels of deltoid activity in relation to supraspinatus activity, such as the empty can and prone full can exercise, may be detrimental. This is due to the increased amount of supe-



there are several reasons why the full can exercise may be preferred over the empty can exercise during rehabilitation and supraspinatus testing. Anatomically, the IR of the humerus during the empty can exercise does not allow the greater tuberosity to clear from under the acromion during arm elevation, which may increase subacromial impingement risk because of decreased subacromial space width.^{15,23,71}

Biomechanically, shoulder abduction performed in extreme IR progressively decreases the abduction moment arm of the supraspinatus from 0° to 90° of abduction.⁵⁰ A diminished mechanical advantage may result in the supraspinatus needing to generate more force, thus increasing the tensile stresses in the injured or healing tendon. This may also make the exercise more challenging for patients with weakness, facilitating compensatory movements such as a shoulder “shrug.”

Scapular kinematics are also different between these exercises, with scapular IR, or “winging” (which occurs in the transverse plane with the scapular medial border moving posterior away from the trunk) and anterior tilt (which occurs in the sagittal plane with the scapular inferior angle moving posterior away from the trunk) being greater with the empty can compared to the full can exercise.⁷⁸ This occurs in part because IR of the humerus in the empty can position tensions both the posteroinferior capsule of the glenohumeral joint and the rotator cuff (primarily the infraspinatus). Tension in these structures contributes to anterior tilt and IR of the scapula, which contribute to scapular protraction. This is clinically important because scapular protraction has been shown to decrease the width of the subacromial space, increasing the risk of subacromial impingement.⁷⁶ In contrast, scapular retraction has been shown to both increase subacromial space width⁷⁶ and increase supraspinatus strength potential (enhanced mechanical advantage), when compared to a more protracted position.⁴¹ These data also emphasize the importance of

rior humeral head migration that may be observed when the rotator cuff does not adequately compress the humerus within the glenoid fossa to counteract, or oppose, the superior pull of the deltoid (FIGURE 1).⁶¹ Poppen and Walker⁶⁶ have shown that the empty can exercise results in a greater superior-orientated force vector than the full can exercise (FIGURE 2). This superior humeral head migration may result in subacromial impingement, subdeltoid bursa trauma,

bursal thickening, and may result in tendon degeneration and eventual failure.²¹ Clinically, superior humeral head migration may be disadvantageous to patients with rotator cuff pathology or a deficiency in glenohumeral dynamic stabilization that are symptomatic. This may partially explain why the empty can position often elicits a certain amount of pain and discomfort in patients.

In addition to the altered ratio of supraspinatus to deltoid muscle activity,

strengthening the scapular retractors and maintaining a scapular retracted posture during shoulder exercises. The authors routinely instruct patients to emphasize an upright posture and a retracted position of the scapula during all shoulder and scapula strengthening exercises.

Thus, the full can exercise appears to be the most advantageous exercise while the empty can exercise is not commonly recommended. The prone full can exercise warrants further consideration because the exercise results in greater EMG signal of the posterior deltoid than the middle deltoid, which may result in less superior shear force. The prone full can exercise may also be beneficial because of scapular muscle recruitment.

Infraspinatus and Teres Minor

The infraspinatus and teres minor comprise the posterior cuff, which provides glenohumeral compression and resists superior and anterior humeral head translation by exerting an inferoposterior force on the humeral head.⁷⁴ The posterior cuff muscles provide glenohumeral ER, which functionally helps clear the greater tuberosity from under the coracoacromial arch during overhead movements, thus minimizing subacromial impingement.

Based on 3-D biomechanical shoulder models, the maximum predicted isometric infraspinatus force was 723 N for ER at 90° of abduction and 909 N for ER at 0° of abduction.³⁴ The maximum predicted teres minor force was much less than for the infraspinatus during maximum ER at both 90° (111 N) and 0° abduction (159 N).³⁴ The effectiveness of the muscles of the posterior rotator cuff to externally rotate the arm depends on glenohumeral position. The superior, middle, and inferior heads of the infraspinatus have their largest ER moment arm (approximately 2.2 cm) and generate their greatest torque at 0° abduction.⁶⁵ As the abduction angle increases, the moment arms of the inferior and middle heads stay relatively constant, while the moment arm of the superior head progressively decreases

until it is about 1.3 cm at 60° abduction.⁶⁵ These data imply that the infraspinatus is a more effective external rotator at lower shoulder abduction angles. The teres minor has a relatively constant ER moment arm (approximately 2.1 cm) and the ability to generate torque throughout shoulder abduction movement, which implies that shoulder abduction angle does not affect the effectiveness of the teres minor to generate ER torque.⁶⁵

Several studies have been designed to test the results of the model; but, as in studies on the supraspinatus, variations in experimental methodology have resulted in conflicting results and controversy in exercise selection.^{3,5,17,19,27,33,44,54,63,70,77,79,81} Several exercises have been recommended based on EMG data, including shoulder ER in the side-lying,^{3,70,79} standing,^{27,70} or prone^{3,70} positions performed at 0°,^{3,70} 45°,^{27,70} and 90°^{3,70} of abduction. Another exercise that has been shown to generate a high EMG signal of the infraspinatus and teres minor is prone horizontal abduction with ER.^{5,79}

Reinold et al⁷⁰ analyzed several different exercises commonly used to strengthen the shoulder external rotators to determine the most effective exercise and position to recruit muscle activity of the posterior rotator cuff. The authors report that the exercise that elicited the most combined EMG signal for the infraspinatus and teres minor was shoulder ER in side-lying (infraspinatus, 62% maximal voluntary isometric contraction [MVIC]; teres minor, 67% MVIC), followed closely by standing ER in the scapular plane at 45° of abduction (infraspinatus, 53% MVIC; teres minor, 55% MVIC), and finally prone ER in the 90° abducted position (infraspinatus, 50% MVIC; teres minor, 48% MVIC).

Exercises in the 90° abducted position are often incorporated to simulate the position and strain on the shoulder during overhead activities such as throwing. This position produced moderate activity of the external rotators but also increased activity of the deltoid and supraspinatus. It appears that the amount

of infraspinatus and teres minor activity progressively decreases as the shoulder moves into an abducted position, while activity of the supraspinatus and deltoid increases. This suggests that as the arm moves into a position of increased vulnerability away from the body, the supraspinatus and deltoid are active to assist in the ER movement, while providing some degree of glenohumeral stability through muscular contraction.

While standing ER exercises performed at 90° of shoulder abduction may have a functional advantage over exercises performed at 0° of shoulder abduction or performed in the scapular plane, due to the close replication in sporting activities, the combination of shoulder abduction and ER places strain on the shoulder capsule, particularly the anterior band of the inferior glenohumeral ligament.^{30,85,86} The clinician must carefully consider this when designing programs for patients with capsulolabral pathology.

Side-lying ER may be the optimal exercise to strengthen the external rotators based on the previously mentioned studies. The inclusion of this exercise should be considered in all exercise programs attempting to increase ER strength or decrease capsular strain.

Theoretically, ER performed at 0° of shoulder abduction with a towel roll between the rib cage and the arm provides both the low capsular strain and also a good balance between the muscles that externally rotate the arm and the muscles that adduct the arm to hold the towel. Our clinical experience has shown that adding a towel roll to the ER exercise provides assistance to the patient by ensuring that proper technique is observed without muscle substitution. Reinold et al⁷⁰ report that adding a towel roll to the exercise consistently exhibited a tendency towards higher activity of the posterior rotator cuff muscles as well. An increase of 20% to 25% in EMG signal of the infraspinatus and teres minor was noted when using the towel roll compared to no towel roll.

What is not readily apparent is the

significant role of the infraspinatus as a shoulder abductor in the scapular plane.^{34,50,65} From 3-D biomechanical shoulder models, predicted infraspinatus force during maximum isometric effort scapular plane abduction (90° position) was 205 N, nearly twice the predicted force from the supraspinatus in this position.³⁴ Liu et al⁵⁰ reported that in scapular plane abduction with neutral rotation the infraspinatus has an abductor moment arm that was small at 0° abduction, but increased to 1 cm at 15° abduction, and remained fairly constant throughout increasing abduction angles. Moreover, infraspinatus activity increases as resistance increases, peaking at 30° to 60° for any given resistance.¹ As resistance increases, infraspinatus activity increases to help generate a higher shoulder scapular abduction torque, and, at lower elevation angles, infraspinatus activity increases to resist superior humeral head translation due to the action of the deltoid.⁷⁴

In contrast to the infraspinatus, the teres minor generates a weak shoulder adductor torque due to its relatively lower attachments to the scapula and humerus.^{34,50,65} A 3-D biomechanical model of the shoulder reveals that the teres minor does not generate scapular plane abduction torque when it contracts, but, rather, generates an adduction torque and 94 N of force during maximum effort scapular plane adduction.³⁴ In addition, Otis et al⁶⁵ reported that the adductor moment arm of the teres minor was approximately 0.2 cm at 45° of IR and approximately 0.1 cm at 45° of ER. These data imply that the teres minor is a weak adductor of the humerus, regardless of the rotational position of the humerus. In addition, because of its posterior position at the shoulder, it also helps generate a weak horizontal abduction torque. Therefore, although its activity is similar to the infraspinatus during ER, it is hypothesized that the teres minor would not be as active as the infraspinatus during scapular abduction, abduction, and flexion movements, but would show ac-

tivity similar to that of the infraspinatus during horizontal abduction. This hypothesis is supported by EMG and magnetic resonance imaging data, which show that teres minor activity during flexion, abduction, and scapular abduction is drastically less than infraspinatus activity.^{1,3,5,54,77,79} Even though the teres minor generates an adduction torque, it is active during these different elevation-type movements, as it likely acts to enhance joint stability by resisting superior humeral head translation and providing humeral head compression within the glenoid fossa.⁷⁴ This is especially likely the case at lower shoulder abduction angles and when abduction and scapular abduction movements are performed against greater resistance.¹ In contrast to the movements of shoulder abduction, scapular abduction, and flexion, teres minor activity is much higher during prone horizontal abduction at 100° abduction with ER, exhibiting similar activity as the infraspinatus.^{5,54,70,77,79}

Subscapularis

The subscapularis provides glenohumeral compression, IR, and anterior stability of the shoulder. From 3-D biomechanical shoulder models, predicted subscapularis force during maximum effort IR was 1725 N at 90° abduction and 1297 N at 0° abduction.³⁴ Its superior, middle, and inferior heads all have their largest IR moment arm (approximately 2.5 cm) and torque generation at 0° abduction.⁶⁵ As the abduction angle increases, the moment arms of the inferior and middle heads stay relatively constant, while the moment arm of the superior head progressively decreases until it is about 1.3 cm at 60° abduction.⁶⁵ These data imply that the upper portion of the subscapularis muscle (innervated by the upper subscapularis nerve) may be a more effective internal rotator at lower abduction angles compared to higher abduction angles. However, there is no significant difference in upper subscapularis activity among IR exercises performed at 0°, 45°, or 90° abduction.^{17,39} Abduction

angle does not appear to affect the ability of the lower subscapularis (innervated by the lower subscapularis nerve) to generate IR torque.⁶⁵ However, lower subscapularis muscle activity is affected by abduction angle, where some EMG data show significantly greater activity with IR at 0° abduction compared to IR at 90° abduction,¹⁷ while EMG data of another study show greater activity with IR exercise performed at 90° compared to 0° abduction.³⁹ Performing IR at 0° abduction produces similar amounts of upper and lower subscapularis activity.^{17,28,39}

Although biomechanical data remain inconclusive as to which position to perform IR exercises (0° versus 90° abduction), during IR at 0° abduction the action of the subscapularis is assisted by several large muscles, such as the pectoralis major, latissimus dorsi, and teres major.¹⁷ Clinically, this may allow for compensation of larger muscles during the exercise in the presence of subscapularis weakness. Decker et al¹⁷ demonstrated that IR at 90° abduction produced less pectoralis major activity compared to 0° abduction. The authors' findings revealed that pectoralis major and latissimus dorsi activity increased when performing IR exercises in an adducted position or while moving into an adducted position during the exercise. Thus, IR at 90° abduction may be performed if attempting to strengthen the subscapularis while minimizing larger muscle group activity.

The subscapularis is active in numerous shoulder exercises other than specific IR of the shoulder. Decker et al¹⁷ reported high subscapularis activity during the push-up with plus and dynamic-hug exercises. These authors also described another exercise that consistently produced high levels of subscapularis activity, which they called the "diagonal exercise" (FIGURE 3). Relatively high subscapularis activity has been measured while performing side-lying shoulder abduction, standing shoulder extension from 90° to 0°, military press, D2 diagonal proprioceptive neuromuscular facilitation (PNF) pattern flexion and extension, and PNF scapular




FIGURE 3. Diagonal exercise for the subscapularis begins in shoulder external rotation at 90° abduction in the coronal plane (A) and internal rotation and horizontal adduction are performed simultaneously (B), similar to a tennis swing.

clock, depression, elevation, protraction, and retraction movements.^{17,33,44,63,75,79}

The subscapularis also generates an abduction torque during arm elevation.^{50,65} From 3-D biomechanical shoulder models, predicted subscapularis force during maximum effort scapular plane abduction at 90° was 283 N, approximately 2.5 times the predicted force for the supraspinatus in this position.³⁴ This was similar to that of the infraspinatus, highlighting the theoretical force couple that the 2 muscles provide to center the humeral head within the glenoid fossa during abduction. Liu et al⁵⁰ reported that in scapular plane abduction with neutral rotation the subscapularis had a peak abductor moment arm of 1 cm at 0° abduction, which slowly decreased to 0 cm at 60° abduction. Moreover, the abductor moment arm of the subscapularis generally decreased as abduction was performed with greater shoulder IR,⁵⁰ such as performing the empty can exercise. In contrast, the abductor moment arm of the subscapularis generally increased as abduction was performed with greater shoulder ER, similar to performing the full can exercise.

Otis et al⁶⁵ reported that the superior, middle, and inferior heads of the sub-

scapularis all have an abductor moment arm (greatest for the superior head and least for the inferior head) that varies as a function of humeral rotation. The lengths of the moment arm for the 3 muscle heads are approximately 0.4 to 2.2 cm at 45° of ER, 0.4 to 1.4 cm in neutral rotation, and 0.4 to 0.5 cm at 45° of IR. These data suggest that the subscapularis is most effective as a scapular plane abductor with the shoulder in ER and least effective with the shoulder in IR. Therefore, the simultaneous activation of the subscapularis and infraspinatus during arm elevation generates both an abductor moment and an inferiorly directed force to the humeral head to resist superior humeral head translation.⁷⁴ In addition, a simultaneous activation neutralizes the IR and ER torques these muscles generate, further enhancing joint stability.

DELTOID

THE DELTOID PLAYS AN IMPORTANT role in shoulder biomechanics and during glenohumeral and scapulothoracic exercises. Extensive research has been conducted on deltoid activity during upper extremity weight-lifting exercises, such as bench press, dumb-

bell flies, military press, and push-ups.^{4,13,16,19,44,57,63,79,81,83}

The abductor moment arm is approximately 0 cm for the anterior deltoid and 1.4 cm for the middle deltoid when the shoulder is in 0° abduction and neutral rotation in the scapular plane.^{50,65} The magnitude of these moment arms progressively increases with shoulder abduction, such that, by 60° of abduction, they are approximately 1.5 to 2 cm for the anterior deltoid and 2.7 to 3.2 cm for the middle deltoid. From 0° to 40° of abduction the moment arms for the anterior and middle deltoids are less than the moment arms for the supraspinatus, subscapularis, and infraspinatus.^{50,65} These data suggest that the anterior and middle deltoid are not effective shoulder abductors at low abduction angles and the shoulder in neutral rotation, especially the anterior deltoid. This is in contrast to the supraspinatus and to a lesser extent the infraspinatus and subscapularis, which are more effective shoulder abductors at low abduction angles. These biomechanical data are consistent with EMG data, in which anterior and middle deltoid activity generally peaks between 60° to 90° of abduction in the scapular plane, while supraspinatus, infraspinatus, and subscapularis activity generally peaks between 30° and 60° of shoulder abduction in the scapular plane.¹

The abductor moment arm for the anterior deltoid changes considerably with humeral rotation, increasing with ER and decreasing with IR.⁵⁰ At 60° ER and 0° abduction, a position similar to the beginning of the full can exercise, the anterior deltoid moment arm is 1.5 cm (compared to 0 cm in neutral rotation), which makes the anterior deltoid an effective abductor even at small abduction angles.⁵⁰ By 60° abduction with ER, its moment arm increased to approximately 2.5 cm (compared to approximately 1.5 to 2 cm in neutral rotation).⁵⁰ In contrast, at 60° IR at 0° abduction, a position similar to the beginning of the empty can exercise, its moment arm was

0 cm (the same as with neutral rotation), which suggests that in this position the anterior deltoid is not an effective abductor.⁵⁰

It has been reported that, given a peak isometric abduction torque of 25 N·m at 0° abduction and neutral rotation, up to 35% to 65% of this torque may be generated by the middle deltoid, 30% by the subscapularis, 25% by the supraspinatus, 10% by the infraspinatus, 2% by the anterior deltoid, and 0% by the posterior deltoid.⁵⁰ Interestingly, the rotator cuff provides a significant contribution to the abduction torque. The ineffectiveness of the anterior and posterior deltoids to generate abduction torque with neutral rotation may appear surprising.^{50,65} However, it is important to understand that the low abduction torque for the anterior deltoid does not mean that this muscle is only minimally active. In fact, because the anterior deltoid has an abductor moment arm near 0 cm, the muscle could be very active and generate very high force but very little torque (in 0° abduction this force attempts to translate the humeral head superiorly).

The aforementioned torque data are complemented and supported by muscle force data from Hughes and An.³⁴ These authors reported predicted forces from the deltoid and rotator cuff during maximum effort abduction with the arm 90° abducted and in neutral rotation. Posterior deltoid and teres minor forces were only 2 N and 0 N, respectively, which further demonstrates the ineffectiveness of these muscles as shoulder abductors. In contrast, middle deltoid force was the highest at 434 N, which suggests a high contribution of this muscle during abduction. The anterior deltoid generated the second highest force of 323 N. This may appear surprising given the low abductor torque for this muscle reported above, but it should be re-emphasized that force and torque are not the same, and that the shoulder was positioned at 90° abduction in the study by Hughes and An,³⁴ in contrast to 0° abduction in the study by Liu et al.⁵⁰ As previously mentioned, the mo-

ment arm of the anterior deltoid progressively increases as abduction increases, and it becomes a more effective abductor. It is also important to remember that muscle force is generated not only to generate joint torque, but also to provide stabilization, such as joint compression. Also of interest is the 608-N force that, collectively, the subscapularis (283 N), infraspinatus (205 N), and supraspinatus (117 N) generate. These large forces are generated not only to abduct the shoulder but also to compress and stabilize the joint, and neutralize the superiorly directed force generated by the deltoid at lower abduction angles.

It should also be noted that deltoid muscle force in different shoulder positions may also affect shoulder stability. All 3 heads of the deltoid generate a force that increases shoulder stability at 60° abduction in the scapular plane (helps to stabilize the humeral head in the glenoid fossa) but decreases shoulder stability at 60° abduction in the frontal plane (tends to translate the humeral head anterior).⁴⁸ These data provide evidence for the use of scapular abduction exercises instead of abduction exercises for individuals with anterior instability.

Thus, it appears that the 3 heads of the deltoid have different roles during upper extremity movements and, therefore, different implications for exercise selection. The middle deltoid may have the most significant impact on superior humeral head migration, and exercises with high levels of middle deltoid activity (as well as anterior deltoid activity), such as the empty can exercise, should likely be minimized for most patients. Conversely, high levels of posterior deltoid activity may not be as disadvantageous as high levels of middle or anterior deltoid activity. It does not appear that the posterior deltoid has a significant role in providing abduction or superior humeral head migration. Thus, exercises such as the prone full can, which generates high levels of rotator cuff and posterior deltoid activity, may be both safe and effective for rotator cuff strengthening.

SCAPULOTHORACIC MUSCLES

THE PRIMARY MUSCLES THAT CONTROL scapular movements include the trapezius, serratus anterior, levator scapulae, rhomboids, and pectoralis minor. Appropriate scapular muscle strength and balance are important because the scapula and humerus move together in coordination during arm movement, referred to as scapulohumeral rhythm. During humeral elevation, the scapula upwardly rotates in the frontal plane, rotating approximately 1° for every 2° of humeral elevation until 120° humeral elevation, and thereafter rotates approximately 1° for every 1° humeral elevation until maximal arm elevation, achieving at least 45° to 55° of upward rotation.^{52,58} During humeral elevation, in addition to scapular upward rotation, the scapula also normally tilts posteriorly approximately 20° to 40° in the sagittal plane and externally rotates approximately 15° to 35° in the transverse plane.^{52,58}

When the normal 3-D scapular movements are disrupted by abnormal scapular muscle-firing patterns, fatigue, or injury, it has been hypothesized that the shoulder complex functions less efficiently, leading to injuries to the shoulder, including the glenohumeral joint.^{10,11,12,18,58,76,80,82} During arm elevation in the scapular plane, individuals with subacromial impingement exhibit decreased scapular upward rotation, increased scapular IR (winging) and anterior tilt, and decreased subacromial space width, compared to those without subacromial impingement.^{24,51} Altered scapular muscle activity is commonly associated with impingement syndrome. For example, upper and lower trapezius activity increased and serratus anterior activity decreased in individuals with impingement as compared to those without impingement.⁵¹ Therefore, it is important to include the scapulothoracic musculature in the rehabilitation of patients with shoulder pathology.⁴²

Serratus Anterior

The serratus anterior works with the



FIGURE 4. Dynamic hug exercise for the serratus anterior begins with the elbows in approximately 45° of flexion, the shoulder abducted 60° and internally rotated 45° (A). The humerus is then horizontally adducted by following an arc movement similar to a hugging action, until full shoulder protraction is reached (B).



FIGURE 5. Bilateral serratus anterior punch to 120° abduction begins with hands by the side (A) before extending elbows and elevating shoulders up to 120° of elevation and full protraction (B).

pectoralis minor to protract the scapula and with the upper and lower trapezius to upwardly rotate the scapula. The serratus anterior is an important muscle because it contributes to all components of normal 3-D scapular movements during arm elevation, which includes upward rotation, posterior tilt, and external rotation.^{52,58} The serratus anterior is also important in athletics, such as during overhead throwing, to accelerate the scapula during the acceleration phase of throwing. The serratus anterior also helps stabilize the medial border and inferior angle of the scapula, preventing scapular IR (winging) and anterior tilt.

Several exercises elicit high serratus anterior activity, such as D1 and D2 diagonal PNF pattern flexion, D2 diagonal PNF pattern extension, supine scapular protraction, supine upward scapular punch, military press, push-up plus, glenohumeral IR and ER at 90° abduction, and shoulder flexion, abduction, and

scaption with ER above 120°. ^{16,20,32,62,63} Serratus anterior activity tends to increase in a somewhat linear fashion with arm elevation. ^{2,20,29,52,62} However, increasing arm elevation increases subacromial impingement risk, ^{15,71} and arm elevation at lower abduction angles also generates relatively high serratus anterior activity. ²⁰

It is interesting that performing shoulder IR and ER at 90° of abduction generates relatively high serratus anterior activity, because these exercises are usually thought to primarily work rotator cuff muscles. ^{20,63} However, during IR and ER at 90° abduction the serratus anterior helps stabilize the scapula. It should be noted that the rotator cuff muscles also act to move the scapula (where they originate) in addition to the humerus. For example, the force exerted by the supraspinatus at the supraspinous fossa has the ability to downwardly rotate the scapula if this force is not counterbalanced by the scapulothoracic musculature.

Not surprising is high serratus anterior activity generated during a push-up exercise. When performing the standard push-up, push-up on knees, and wall push-up, serratus anterior activity is greater when full scapular protraction

occurs after the elbows fully extend (push-up plus). ⁵³ Moreover, serratus anterior activity was lowest in the wall push-up plus, exhibited moderate activity during the push-up plus on knees, and relatively high activity during the standard push-up plus. ^{16,53} Compared to the standard push-up, performing a push-up plus with the feet elevated produced significantly greater serratus anterior activity. ⁴⁷ These findings demonstrate that serratus anterior activity increases as the positional (gravitational) challenge increases.

Decker et al¹⁶ compared several common exercises designed to recruit the serratus anterior. The authors identified that the 3 exercises that produced the greatest serratus anterior EMG signal were the push-up with a plus, dynamic hug (FIGURE 4), and punch exercises (similar to a jabbing protraction motion).

Ekstrom²⁰ also looked at the activity of the serratus anterior during common exercises. His data indicated that the serratus anterior is more active when performing a movement that simultaneously creates scapular upward rotation and protraction, as with the serratus anterior punch performed at 120° of abduc-

tion and during a diagonal exercise that incorporated protraction with shoulder flexion, horizontal adduction, and external rotation. It appears that the punch exercise can be enhanced by starting at 0° abduction and extending the elbow, while elevating and protracting the shoulder (FIGURE 5).

Hardwick et al²⁹ compared the wall push-up plus, full can, and a wall slide exercise. The wall slide begins by slightly leaning against the wall with the ulnar border of the forearms in contact with the wall, elbows flexed 90°, and shoulders abducted 90° in the scapular plane. From this position the arms slide up the wall in the scapular plane, while leaning into the wall. Interestingly, the wall slide produce similar serratus anterior activity compared to scapular abduction above 120° abduction with no resistance. One advantage of the wall slide compared to scapular abduction is that, anecdotally, patients report that the wall slide is less painful to perform.²⁹ This may be because during the wall slide the upper extremities are supported against the wall, making it easier to perform while also assisting with compression of the humeral head within the glenoid. Thus, this may be an effective exercise to perform during the earlier protective phases of some rehabilitation programs.

Trapezius

General functions of the trapezius include scapular upward rotation and elevation for the upper trapezius, retraction for the middle trapezius, and upward rotation and depression for the lower trapezius. In addition, the inferomedial-directed fibers of the lower trapezius may also contribute to posterior tilt and external rotation of the scapula during arm elevation,⁵² which decreases subacromial impingement risk^{24,51} and makes the lower trapezius an important area of focus in rehabilitation. Relatively high upper trapezius activity occurs in the shoulder shrug, prone rowing, prone horizontal abduction at 90° and 135° of abduction with ER and IR, D1 diagonal PNF pat-

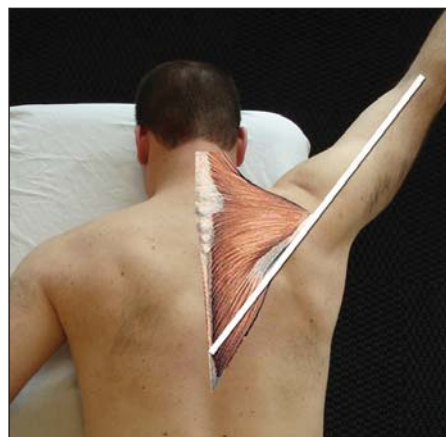


FIGURE 6. The proper alignment of the upper extremity during the prone horizontal abduction exercise with external rotation. Note how the upper extremity is aligned with the muscle fiber orientation of the lower trapezius.

tern flexion, standing scapular dynamic hug, PNF scapular clock, military press, 2-hand overhead medicine ball throw, and scapular abduction and abduction below 80°, at 90°, and above 120° with ER.^{13,16,20,62,75} During scapular abduction, upper trapezius activity progressively increases from 0° to 60°, remains relatively constant from 60° to 120°, and continues to progressively increase from 120° to 180°.²

Relatively high middle trapezius activity occurs with shoulder shrug, prone rowing, and prone horizontal abduction at 90° and 135° abduction with ER and IR.^{20,62} Some authors have reported relatively high middle trapezius activity during scapular abduction at 90° and above 120°,^{2,16,20} while authors of another study showed low EMG signal amplitude of the middle trapezius during this exercise.⁶²

Relatively high lower trapezius activity occurs in the prone rowing, prone horizontal abduction at 90° and 135° abduction with ER and IR, prone and standing ER at 90° abduction, D2 diagonal PNF pattern flexion and extension, PNF scapular clock, standing high scapular rows, and scapular abduction, flexion, and abduction below 80° and above 120° with ER.^{20,62,63,75} Lower trapezius activity tends to be relatively low at angles less than 90° of scapular abduction, abduction, and flexion, and then increases exponentially

from 90° to 180°.^{2,20,29,62,75,84} Significantly greater lower trapezius activity has been reported during the prone ER at 90° abduction exercise compared to the empty can exercise.³ As previously mentioned, the lower trapezius is an extremely important muscle in shoulder function due to its role in scapular upward rotation, external rotation, and posterior tilt.

Ekstrom et al²⁰ reported that the greatest EMG signal amplitude of the lower trapezius occurred during the prone full can, prone ER at 90°, and prone horizontal abduction at 90° with ER exercises. Based on these results, it appears that the prone full can exercise should not be performed at a set degree of abduction, but should be individualized based on the alignment of the lower trapezius fibers (FIGURE 6). In the authors' experience, this is typically around 120° of abduction but may fluctuate, depending on the specific patient and body type.

It is often clinically beneficial to enhance the ratio of lower trapezius-to-upper trapezius strength.¹¹ In the opinion of the authors, poor posture and muscle imbalance often seen in patients with a variety of shoulder pathologies is often the result of poor muscle balance between the upper and lower trapezius, with the upper trapezius being more dominant. McCabe et al⁵⁶ report that bilateral ER at 0° abduction resulted in the greatest lower trapezius-upper trapezius ratio compared to several other similar trapezius exercises (FIGURE 7). Cools et al¹¹ also identified side-lying ER and prone horizontal abduction at 90° abduction and ER as 2 beneficial exercises to enhance the ratio of lower trapezius to upper trapezius activity.

Rhomboids and Levator Scapulae

Both the rhomboids and levator scapulae function as scapular retractors, downward rotators, and elevators. Exercises used to strengthen rotator cuff and scapulohoracic musculature are also effective in eliciting activity of the rhomboids and levator scapulae. Relatively high rhomboid activity has been



FIGURE 7. Bilateral external rotation for infraspinatus and lower trapezius strengthening involves grasping exercise tubing with both hands and externally rotating. Emphasis should be placed on providing scapular retraction and posterior tilting.

reported during D2 diagonal PNF pattern flexion and extension, standing shoulder ER at 0° and 90° abduction, standing shoulder IR at 90° abduction, standing shoulder extension from 90° to 0°, prone shoulder horizontal abduction at 90° abduction with IR, scapular abduction, abduction, and shoulder flexion above 120° with ER, prone rowing, and standing high, mid, and low scapular rows.^{62,63} Relatively high rhomboids and levator scapulae activity has been reported with scapular abduction above 120° with ER, prone horizontal abduction at 90° abduction with ER and IR, prone rowing, and prone extension at 90° flexion.⁶² Therefore, the prone extension exercise may be performed in addition to many of the previously mentioned exercises for other scapulothoracic muscles. Other specific exercises to activate the rhomboids and levator scapulae muscles are not often necessary to perform.

RECOMMENDATIONS

THE PRECEDING REVIEW CAN BE USED to identify appropriate rehabilitation exercises for specific muscles. Based on the reported studies and the collective experience of the authors, we recommend that exercises should be selected based on the appropriate anatomical, biomechanical, and clinical implications. We have identified a set of exercises that the current authors use clinically for rehabilitation and injury prevention (TABLE). These exercises have been selected based on the results of the numerous studies previously cited and take into consideration these implications for each exercise described. Furthermore, the authors encourage the clinician to carefully consider emphasizing posture and scapular retraction during the performance of glenohumeral and scapulothoracic exercises.

A common recommendation in rehabilitation is to limit the amount of weight used during glenohumeral and scapulothoracic exercises to assure that the appropriate muscles are being utilized and not larger compensatory muscles. Two recent studies have analyzed this theory and appear to prove the recommendation inaccurate and not necessary. Alpert et al⁷ studied the rotator cuff and deltoid muscles during scapular plane elevation and noted that EMG signal amplitude of the smaller rotator cuff muscles and larger deltoid muscles increased linearly in relation to the amount of weight used. This finding is consistent with that of Dark et al,¹⁴ who showed similar results for the rotator cuff, deltoid, pectoralis, and latissimus dorsi during ER and IR at 0° abduction. Thus, it appears that larger muscle groups do not overpower smaller groups, such as the rotator cuff. Weight selection should be based on the individual goals and performance of each patient. It does not appear necessary to limit the amount of weight performed during these rotator cuff exercises.

As our understanding of the anatomical and biomechanical implications associated with exercise selection continues

to grow, we are seeing advances in exercise selection and the integration of the whole-body kinetic-chain approach to strengthening and rehabilitating injuries. This may involve strengthening multiple joints simultaneously and during movement patterns that mimic athletic and functional daily activities of living. The authors often employ these techniques when our patients improve in strength yet continue to have symptoms during activities. In addition, we often attempt to further challenge our patients by performing many of the recommended exercise on various unstable surfaces (such as foam or physioballs), with altered bases of support (such as sitting, standing, or single-leg balancing), in an attempt to recruit whole-body muscle patterns that interact together to perform active range of motion while stabilizing other areas of the body. We believe that these concepts are important to consider in addition to straight-plane, isolated movements of specific muscle groups, and that strength, posture, balance, and neuromuscular control are all vital components to any injury prevention of rehabilitation program. Future research on the validity of these techniques is needed to justify their use. We believe that this is the next step in the evolution of research on the clinical and biomechanical implications of exercise selection for the glenohumeral and scapulothoracic musculature.

CONCLUSION

A THOROUGH UNDERSTANDING OF the biomechanical factors associated with normal shoulder movement, as well as during commonly performed exercises, is necessary to safely and effectively design appropriate programs. We have reviewed the normal biomechanics of the glenohumeral and scapulothoracic muscles during functional activities, common exercises, and in the presence of pathology. These findings can be used by the clinician to design appropriate rehabilitation and injury prevention programs. ●

TABLE

**RECOMMENDED EXERCISES FOR GLENOHUMERAL AND SCAPULOTHORACIC MUSCLES
BASED ON ANATOMICAL, BIOMECHANICAL, AND CLINICAL IMPLICATIONS**

Muscle	Exercise	Anatomical Implications	Biomechanical Implications	Clinical Implications
Supraspinatus	1. Full can	1. Enhances scapular position and subacromial space	1. Decreased deltoid involvement compared to empty can	1. Minimizes chance of superior humeral head migration by deltoid overpowering supraspinatus
	2. Prone full can	2. Enhances scapular position and subacromial space	2. High posterior deltoid activity with similar supraspinatus activity	2. High supraspinatus activity and also good exercise for lower trapezius
Infraspinatus and teres minor	1. Side-lying ER	1. Position of shoulder stability, minimal capsular strain	1. Increased moment arm of muscle at 0° abduction. Greatest EMG activity	1. Most effective exercise in recruiting infraspinatus activity. Good when cautious with static stability
	2. Prone ER at 90° abduction	2. Challenging position for stability, higher capsular strain	2. High EMG activity	2. Strengthens in a challenging position for shoulder stability. Also good exercise for lower trapezius
	3. ER with towel roll	3. Allows for proper form without compensation	3. Increased EMG activity with addition of towel, also incorporates adductors	3. Enhances muscle recruitment and synergy with adductors
Subscapularis	1. IR at 0° abduction	1. Position of shoulder stability	1. Similar subscapularis activity between 0° and 90° abduction	1. Effective exercise, good when cautious with static stability
	2. IR at 90° abduction	2. Position of shoulder instability	2. Enhances scapular position and subacromial space. Less pectoralis activity	2. Strengthens in a challenging position for shoulder stability
	3. IR diagonal exercise	3. Replicates more functional activity	3. High EMG activity	3. Effective strengthening in a functional movement pattern
Serratus anterior	1. Push-up with plus	1. Easy position to produce resistance against protraction	1. High EMG activity	1. Effective exercise to provide resistance against protraction, also good exercise for subscapularis
	2. Dynamic hug	2. Performed below 90° abduction	2. High EMG activity	2. Easily perform in patients with difficulty elevating arms or performing push-up. Also good exercise for subscapularis
	3. Serratus punch 120°	3. Combines protraction with upward rotation	3. High EMG activity	3. Good dynamic activity to combine upward rotation and protraction function
Lower trapezius	1. Prone full can	1. Can properly align exercise with muscle fibers	1. High EMG activity	1. Effective exercise, also good exercise for supraspinatus
	2. Prone ER at 90° abduction	2. Prone exercise below 90° abduction	2. High EMG activity	2. Effective exercise, also good exercise for infraspinatus and teres minor
	3. Prone horizontal abduction at 90° abduction with ER	3. Prone exercise below 90° abduction	3. Good ratio of lower to upper trapezius activity	3. Effective exercise, also good exercise for middle trapezius
	4. Bilateral ER	4. Scapular control without arm elevation	4. Good ratio of lower to upper trapezius activity	4. Effective exercise, also good for infraspinatus and teres minor
Middle trapezius	1. Prone row	1. Prone exercise below 90° abduction	1. High EMG activity	1. Effective exercise, good ratios of upper, middle, and lower trapezius activity
	2. Prone horizontal abduction at 90° abduction with ER	2. Prone exercise below 90° abduction	2. High EMG activity	2. Effective exercise, also good exercise for lower trapezius
Upper trapezius	1. Shrug	1. Scapular control without arm elevation	1. High EMG activity	1. Effective exercise
	2. Prone row	2. Prone exercise below 90° abduction	2. High EMG activity	2. Good ratios of upper, middle, and lower trapezius activity
	3. Prone horizontal abduction at 90° abduction with ER	3. Prone exercise below 90° abduction	3. High EMG activity	3. Effective exercise, also good exercise for lower trapezius
Rhomboids and levator scapulae	1. Prone row	1. Prone exercise below 90° abduction	1. High EMG activity	1. Effective exercise, good ratios of upper, middle, and lower trapezius activity
	2. Prone horizontal abduction at 90° abduction with ER	2. Prone exercise below 90° abduction	2. High EMG activity	2. Effective exercise, also good for lower and middle trapezius
	3. Prone extension with ER	3. Prone exercise below 90° abduction	3. High EMG activity	3. Effective exercise, unique movement to enhance scapular control

Abbreviations: EMG, electromyography; ER, external rotation; IR, internal rotation.

REFERENCES

1. Alpert SW, Pink MM, Jobe FW, McMahon PJ, Mathiyakom W. Electromyographic analysis of deltoid and rotator cuff function under varying loads and speeds. *J Shoulder Elbow Surg.* 2000;9:47-58.
2. Bagg SD, Forrest WJ. Electromyographic study of the scapular rotators during arm abduction in the scapular plane. *Am J Phys Med.* 1986;65:111-124.
3. Ballantyne BT, O'Hare SJ, Paschall JL, Et al. Electromyographic activity of selected shoulder muscles in commonly used therapeutic exercises. *Phys Ther.* 1993;73:668-682.
4. Barnett C, Kippers V, Turner P. Effects of variations of the pench press exercise on the EMG activity of five shoulder muscles. *J Strength Cond Res.* 1995;9:222-227.
5. Blackburn TA, McLeod WD, White B, Wofford L. EMG analysis of posterior rotator cuff exercises. *Athl Train J Natl Athl Train Assoc.* 1990;25:40-45.
6. Brosmann J, Preidler KW, Pedowitz RA, White LM, Trudell D, Resnick D. Shoulder impingement syndrome: influence of shoulder position on rotator cuff impingement—an anatomic study. *AJR Am J Roentgenol.* 1996;167:1511-1515.
7. Brostrom LA, Kronberg M, Nemeth G. Muscle activity during shoulder dislocation. *Acta Orthop Scand.* 1989;60:639-641.
8. Burke WS, Vangsness CT, Powers CM. Strengthening the supraspinatus: a clinical and biomechanical review. *Clin Orthop Relat Res.* 2002;292-298.
9. Cain PR, Mutschler TA, Fu FH, Lee SK. Anterior stability of the glenohumeral joint. A dynamic model. *Am J Sports Med.* 1987;15:144-148.
10. Cools AM, Declercq GA, Cambier DC, Mahieu NN, Witvrouw EE. Trapezius activity and intramuscular balance during isokinetic exercise in overhead athletes with impingement symptoms. *Scand J Med Sci Sports.* 2007;17:25-33. <http://dx.doi.org/10.1111/j.1600-0838.2006.00570.x>
11. Cools AM, Dewitte V, Lanszweert F, et al. Rehabilitation of scapular muscle balance: which exercises to prescribe? *Am J Sports Med.* 2007;35:1744-1751. <http://dx.doi.org/10.1177/0363546507303560>
12. Cools AM, Witvrouw EE, Declercq GA, Danneels LA, Cambier DC. Scapular muscle recruitment patterns: trapezius muscle latency with and without impingement symptoms. *Am J Sports Med.* 2003;31:542-549.
13. Cordasco FA, Wolfe IN, Wootten ME, Bigliani LU. An electromyographic analysis of the shoulder during a medicine ball rehabilitation program. *Am J Sports Med.* 1996;24:386-392.
14. Dark A, Ginn KA, Halaki M. Shoulder muscle recruitment patterns during commonly used rotator cuff exercises: an electromyographic study. *Phys Ther.* 2007;87:1039-1046. <http://dx.doi.org/10.2522/ptj.20060068>
15. De Wilde L, Plasschaert F, Berghs B, Van Hoecke M, Verstraete K, Verdonk R. Quantified measurement of subacromial impingement. *J Shoulder Elbow Surg.* 2003;12:346-349. <http://dx.doi.org/10.1016/mse.2003.S1058274603000387>
16. Decker MJ, Hintermeister RA, Faber KJ, Hawkins RJ. Serratus anterior muscle activity during selected rehabilitation exercises. *Am J Sports Med.* 1999;27:784-791.
17. Decker MJ, Tokish JM, Ellis HB, Torry MR, Hawkins RJ. Subscapularis muscle activity during selected rehabilitation exercises. *Am J Sports Med.* 2003;31:126-134.
18. Ebaugh DD, McClure PW, Karduna AR. Scapulothoracic and glenohumeral kinematics following an external rotation fatigue protocol. *J Orthop Sports Phys Ther.* 2006;36:557-571. <http://dx.doi.org/10.2519/jospt.2006.2189>
19. Ekholm J, Arborelius UP, Hillered L, Ortvist A. Shoulder muscle EMG and resisting moment during diagonal exercise movements resisted by weight-and-pulley-circuit. *Scand J Rehabil Med.* 1978;10:179-185.
20. Ekstrom RA, Donatelli RA, Soderberg GL. Surface electromyographic analysis of exercises for the trapezius and serratus anterior muscles. *J Orthop Sports Phys Ther.* 2003;33:247-258.
21. Flatow EL, Soslosky LJ, Ticker JB, et al. Excursion of the rotator cuff under the acromion. Patterns of subacromial contact. *Am J Sports Med.* 1994;22:779-788.
22. Glousman R, Jobe F, Tibone J, Moynes D, Antonelli D, Perry J. Dynamic electromyographic analysis of the throwing shoulder with glenohumeral instability. *J Bone Joint Surg Am.* 1988;70:220-226.
23. Graichen H, Bonel H, Stammberger T, Englmeier KH, Reiser M, Eckstein F. Subacromial space width changes during abduction and rotation—a 3-D MR imaging study. *Surg Radiol Anat.* 1999;21:59-64.
24. Graichen H, Bonel H, Stammberger T, et al. Three-dimensional analysis of the width of the subacromial space in healthy subjects and patients with impingement syndrome. *AJR Am J Roentgenol.* 1999;172:1081-1086.
25. Graichen H, Hinterwimmer S, von Eisenhart-Rothe R, Vogl T, Englmeier KH, Eckstein F. Effect of abducting and adducting muscle activity on glenohumeral translation, scapular kinematics and subacromial space width in vivo. *J Biomech.* 2005;38:755-760. <http://dx.doi.org/10.1016/j.jbiomech.2004.05.020>
26. Graichen H, Stammberger T, Bonel H, Karl-Hans E, Reiser M, Eckstein F. Glenohumeral translation during active and passive elevation of the shoulder: a 3D open-MRI study. *J Biomech.* 2000;33:609-613.
27. Greenfield BH, Donatelli R, Wooden MJ, Wilkes J. Isokinetic evaluation of shoulder rotational strength between the plane of scapula and the frontal plane. *Am J Sports Med.* 1990;18:124-128.
28. Greis PE, Kuhn JE, Schultheis J, Hintermeister R, Hawkins R. Validation of the lift-off test and analysis of subscapularis activity during maximal internal rotation. *Am J Sports Med.* 1996;24:589-593.
29. Hardwick DH, Beebe JA, McDonnell MK, Lang CE. A comparison of serratus anterior muscle activation during a wall slide exercise and other traditional exercises. *J Orthop Sports Phys Ther.* 2006;36:903-910. <http://dx.doi.org/10.2519/jospt.2006.2306>
30. Harryman DT, 2nd, Sidles JA, Clark JM, McQuade KJ, Gibb TD, Matsen FA, 3rd. Translation of the humeral head on the glenoid with passive glenohumeral motion. *J Bone Joint Surg Am.* 1990;72:1334-1343.
31. Hess SA, Richardson C, Darnell R, Friis P, Lisle D, Myers P. Timing of rotator cuff activation during shoulder external rotation in throwers with and without symptoms of pain. *J Orthop Sports Phys Ther.* 2005;35:812-820. <http://dx.doi.org/10.2519/jospt.2005.2134>
32. Hintermeister RA, Lange GW, Schultheis JM, Bey MJ, Hawkins RJ. Electromyographic activity and applied load during shoulder rehabilitation exercises using elastic resistance. *Am J Sports Med.* 1998;26:210-220.
33. Horrigan JM, Shellock FG, Mink JH, Deutsch AL. Magnetic resonance imaging evaluation of muscle usage associated with three exercises for rotator cuff rehabilitation. *Med Sci Sports Exerc.* 1999;31:1361-1366.
34. Hughes RE, An KN. Force analysis of rotator cuff muscles. *Clin Orthop Relat Res.* 1996;75-83.
35. Illyes A, Kiss RM. Electromyographic analysis in patients with multidirectional shoulder instability during pull, forward punch, elevation and overhead throw. *Knee Surg Sports Traumatol Arthrosc.* 2007;15:624-631. <http://dx.doi.org/10.1007/s00167-006-0163-1>
36. Itoi E, Berglund LJ, Grabowski JJ, et al. Tensile properties of the supraspinatus tendon. *J Orthop Res.* 1995;13:578-584. <http://dx.doi.org/10.1002/jor.1100130413>
37. Itoi E, Kido T, Sano A, Urayama M, Sato K. Which is more useful, the "full can test" or the "empty can test," in detecting the torn supraspinatus tendon? *Am J Sports Med.* 1999;27:65-68.
38. Jobe FW, Moynes DR. Delineation of diagnostic criteria and a rehabilitation program for rotator cuff injuries. *Am J Sports Med.* 1982;10:336-339.
39. Kadaba MP, Cole A, Wootten ME, et al. Intramuscular wire electromyography of the subscapularis. *J Orthop Res.* 1992;10:394-397. <http://dx.doi.org/10.1002/jor.1100100312>
40. Kelly BT, Kadmas WR, Speer KP. The manual muscle examination for rotator cuff strength. An electromyographic investigation. *Am J Sports Med.* 1996;24:581-588.
41. Kibler WB, Sciascia A, Dome D. Evaluation of apparent and absolute supraspinatus strength in patients with shoulder injury using the scapular retraction test. *Am J Sports Med.* 2006;34:1643-1647. <http://dx.doi.org/10.1177/0363546506288728>
42. Konrad GG, Jolly JT, Labriola JE, McMahon PJ, Debski RE. Thoracohumeral muscle activity alters glenohumeral joint biomechanics during active abduction. *J Orthop Res.* 2006;24:748-756. <http://dx.doi.org/10.1002/jor.20062>
43. Kronberg M, Brostrom LA, Nemeth G. Differences in shoulder muscle activity between patients with generalized joint laxity and normal controls. *Clin Orthop Relat Res.* 1991;181-192.
44. Kronberg M, Nemeth G, Brostrom LA. Muscle ac-

tivity and coordination in the normal shoulder. An electromyographic study. *Clin Orthop Relat Res*. 1990;76-85.

45. Labriola JE, Jolly JT, McMahon PJ, Debski RE. Active stability of the glenohumeral joint decreases in the apprehension position. *Clin Biomech (Bristol, Avon)*. 2004;19:801-809. <http://dx.doi.org/10.1016/j.clinbiomech.2004.05.008>
46. Labriola JE, Lee TQ, Debski RE, McMahon PJ. Stability and instability of the glenohumeral joint: the role of shoulder muscles. *J Shoulder Elbow Surg*. 2005;14:32S-38S. <http://dx.doi.org/10.1016/j.jse.2004.09.014>
47. Lear LJ, Gross MT. An electromyographical analysis of the scapular stabilizing synergists during a push-up progression. *J Orthop Sports Phys Ther*. 1998;28:146-157.
48. Lee SB, An KN. Dynamic glenohumeral stability provided by three heads of the deltoid muscle. *Clin Orthop Relat Res*. 2002;40-47.
49. Lee SB, Kim KJ, O'Driscoll SW, Morrey BF, An KN. Dynamic glenohumeral stability provided by the rotator cuff muscles in the mid-range and end-range of motion. A study in cadavera. *J Bone Joint Surg Am*. 2000;82:849-857.
50. Liu J, Hughes RE, Smutz WP, Niebur G, Nan-An K. Roles of deltoid and rotator cuff muscles in shoulder elevation. *Clin Biomech (Bristol, Avon)*. 1997;12:32-38.
51. Ludewig PM, Cook TM. Alterations in shoulder kinematics and associated muscle activity in people with symptoms of shoulder impingement. *Phys Ther*. 2000;80:276-291.
52. Ludewig PM, Cook TM, Nawoczenski DA. Three-dimensional scapular orientation and muscle activity at selected positions of humeral elevation. *J Orthop Sports Phys Ther*. 1996;24:57-65.
53. Ludewig PM, Hoff MS, Osowski EE, Meschke SA, Rundquist PJ. Relative balance of serratus anterior and upper trapezius muscle activity during push-up exercises. *Am J Sports Med*. 2004;32:484-493.
54. Malanga GA, Jenp YN, Growney ES, An KN. EMG analysis of shoulder positioning in testing and strengthening the supraspinatus. *Med Sci Sports Exerc*. 1996;28:661-664.
55. Matias R, Pascoal AG. The unstable shoulder in arm elevation: a three-dimensional and electromyographic study in subjects with glenohumeral instability. *Clin Biomech (Bristol, Avon)*. 2006;21 Suppl 1:S52-58. <http://dx.doi.org/10.1016/j.clinbiomech.2005.09.014>
56. McCabe RA. Surface electromyographic analysis of the lower trapezius muscle during exercises performed below ninety degrees of shoulder elevation in healthy subjects. *N Am J Sports Phys Ther*. 2007;2:34-43.
57. McCaw ST, Friday JJ. A comparison of muscle activity between a free weight and machine bench press. *J Strength Cond Res*. 1994;8:259-264.
58. McClure PW, Michener LA, Sennett BJ, Karduna AR. Direct 3-dimensional measurement of scapular kinematics during dynamic movements in vivo. *J Shoulder Elbow Surg*. 2001;10:269-277. <http://dx.doi.org/10.1067/mse.2001.112954>
59. McMahon PJ, Jobe FW, Pink MM, Brault JR, Perry

J. Comparative electromyographic analysis of shoulder muscles during planar motions: anterior glenohumeral instability versus normal. *J Shoulder Elbow Surg*. 1996;5:118-123.

60. Meskers CG, van der Helm FC, Rozing PM. The size of the supraspinatus outlet during elevation of the arm in the frontal and sagittal plane: a 3-D model study. *Clin Biomech (Bristol, Avon)*. 2002;17:257-266.
61. Morrey BF, Itoi E, An KN. Biomechanics of the shoulder. In: Rockwood CA, Matsen FA, 3rd, eds. *The Shoulder*. Philadelphia: Saunders; 1998:233-276.
62. Moseley JB, Jr., Jobe FW, Pink M, Perry J, Tibone J. EMG analysis of the scapular muscles during a shoulder rehabilitation program. *Am J Sports Med*. 1992;20:128-134.
63. Myers JB, Pasquale MR, Laudner KG, Sell TC, Bradley JP, Lephart SM. On-the-field resistance-tubing exercises for throwers: an electromyographic analysis. *J Athl Train*. 2005;40:15-22.
64. Ogston JB, Ludewig PM. Differences in 3-dimensional shoulder kinematics between persons with multidirectional instability and asymptomatic controls. *Am J Sports Med*. 2007;35:1361-1370. <http://dx.doi.org/10.1177/0363546507300820>
65. Otis JC, Jiang CC, Wickiewicz TL, Peterson MG, Warren RF, Santner TJ. Changes in the moment arms of the rotator cuff and deltoid muscles with abduction and rotation. *J Bone Joint Surg Am*. 1994;76:667-676.
66. Poppen NK, Walker PS. Forces at the glenohumeral joint in abduction. *Clin Orthop Relat Res*. 1978;165-170.
67. Poppen NK, Walker PS. Normal and abnormal motion of the shoulder. *J Bone Joint Surg Am*. 1976;58:195-201.
68. Reddy AS, Mohr KJ, Pink MM, Jobe FW. Electromyographic analysis of the deltoid and rotator cuff muscles in persons with subacromial impingement. *J Shoulder Elbow Surg*. 2000;9:519-523.
69. Reinold MM, Macrina LC, Wilk KE, et al. Electromyographic analysis of the supraspinatus and deltoid muscles during 3 common rehabilitation exercises. *J Athl Train*. 2007;42:464-469.
70. Reinold MM, Wilk KE, Fleisig GS, et al. Electromyographic analysis of the rotator cuff and deltoid musculature during common shoulder external rotation exercises. *J Orthop Sports Phys Ther*. 2004;34:385-394. <http://dx.doi.org/10.2519/jospt.2004.0665>
71. Roberts CS, Davila JN, Hushek SG, Tillett ED, Corrigan TM. Magnetic resonance imaging analysis of the subacromial space in the impingement sign positions. *J Shoulder Elbow Surg*. 2002;11:595-599. <http://dx.doi.org/10.1067/mse.2002.127095>
72. Santos MJ, Belangero WD, Almeida GL. The effect of joint instability on latency and recruitment order of the shoulder muscles. *J Electromyogr Kinesiol*. 2007;17:167-175. <http://dx.doi.org/10.1016/j.jelekin.2006.01.010>
73. Scovazzo ML, Browne A, Pink M, Jobe FW, Kerrigan J. The painful shoulder during freestyle swimming. An electromyographic cinematographic analysis of twelve muscles. *Am J Sports Med*. 1991;19:577-582.
74. Sharkey NA, Marder RA. The rotator cuff opposes

superior translation of the humeral head. *Am J Sports Med*. 1995;23:270-275.

75. Smith J, Dahm DL, Kaufman KR, et al. Electromyographic activity in the immobilized shoulder girdle musculature during scapulothoracic exercises. *Arch Phys Med Rehabil*. 2006;87:923-927. <http://dx.doi.org/10.1016/j.apmr.2006.03.013>
76. Solem-Bertoft E, Thuomas KA, Westerberg CE. The influence of scapular retraction and protraction on the width of the subacromial space. An MRI study. *Clin Orthop Relat Res*. 1993;99-103.
77. Takeda Y, Kashiwaguchi S, Endo K, Matsuura T, Sasa T. The most effective exercise for strengthening the supraspinatus muscle: evaluation by magnetic resonance imaging. *Am J Sports Med*. 2002;30:374-381.
78. Thigpen CA, Padua DA, Morgan N, Kreps C, Karas SG. Scapular kinematics during supraspinatus rehabilitation exercise: a comparison of full-can versus empty-can techniques. *Am J Sports Med*. 2006;34:644-652. <http://dx.doi.org/10.1177/0363546505281797>
79. Townsend H, Jobe FW, Pink M, Perry J. Electromyographic analysis of the glenohumeral muscles during a baseball rehabilitation program. *Am J Sports Med*. 1991;19:264-272.
80. Tsai NT, McClure PW, Karduna AR. Effects of muscle fatigue on 3-dimensional scapular kinematics. *Arch Phys Med Rehabil*. 2003;84:1000-1005.
81. Uhl TL, Carver TJ, Mattacola CG, Mair SD, Nitz AJ. Shoulder musculature activation during upper extremity weight-bearing exercise. *J Orthop Sports Phys Ther*. 2003;33:109-117.
82. Warner JJ, Micheli LJ, Arslanian LE, Kennedy J, Kennedy R. Patterns of flexibility, laxity, and strength in normal shoulders and shoulders with instability and impingement. *Am J Sports Med*. 1990;18:366-375.
83. Welsch EA, Bird M, Mayhew JL. Electromyographic activity of the pectoralis major and anterior deltoid muscles during three upper-body lifts. *J Strength Cond Res*. 2005;19:449-452. <http://dx.doi.org/10.1519/14513.1>
84. Wiedenbauer MM, Mortensen OA. An electromyographic study of the trapezius muscle. *Am J Phys Med*. 1952;31:363-372.
85. Wilk KE, Andrews JR, Arrigo CA. The physical examination of the glenohumeral joint: emphasis on the stabilizing structures. *J Orthop Sports Phys Ther*. 1997;25:380-389.
86. Wilk KE, Arrigo CA, Andrews JR. Current concepts: the stabilizing structures of the glenohumeral joint. *J Orthop Sports Phys Ther*. 1997;25:364-379.
87. Worrell TW, Corey BJ, York SL, Santiestaban J. An analysis of supraspinatus EMG activity and shoulder isometric force development. *Med Sci Sports Exerc*. 1992;24:744-748.
88. Wuelker N, Korell M, Thren K. Dynamic glenohumeral joint stability. *J Shoulder Elbow Surg*. 1998;7:43-52.



MORE INFORMATION
WWW.JOSPT.ORG